

American Thyroid Association Guidelines for Management of Patients with Anaplastic Thyroid Cancer

Robert C. Smallridge,^{1,*} Kenneth B. Ain,^{2,3} Sylvia L. Asa,^{4,5} Keith C. Bible,⁶ James D. Brierley,^{4,5}
Kenneth D. Burman,⁷ Electron Kebebew,⁸ Nancy Y. Lee,⁹ Yuri E. Nikiforov,¹⁰ M. Sara Rosenthal,¹¹
Manisha H. Shah,¹² Ashok R. Shaha,⁹ and R. Michael Tuttle⁹

for the American Thyroid Association Anaplastic Thyroid Cancer Guidelines Taskforce

Background: Anaplastic thyroid cancer (ATC) is a rare but highly lethal form of thyroid cancer. Rapid evaluation and establishment of treatment goals are imperative for optimum patient management and require a multidisciplinary team approach. Here we present guidelines for the management of ATC. The development of these guidelines was supported by the American Thyroid Association (ATA), which requested the authors, members of the ATA Taskforce for ATC, to independently develop guidelines for ATC.

Methods: Relevant literature was reviewed, including serial PubMed searches supplemented with additional articles. The quality and strength of recommendations were adapted from the Clinical Guidelines Committee of the American College of Physicians, which in turn was developed by the Grading of Recommendations Assessment, Development and Evaluation workshop.

Results: The guidelines include the diagnosis, initial evaluation, establishment of treatment goals, approaches to locoregional disease (surgery, radiotherapy, systemic therapy, supportive care during active therapy), approaches to advanced/metastatic disease, palliative care options, surveillance and long-term monitoring, and ethical issues including end of life. The guidelines include 65 recommendations.

Conclusions: These are the first comprehensive guidelines for ATC and provide recommendations for management of this extremely aggressive malignancy. Patients with stage IVA/IVB resectable disease have the best prognosis, particularly if a multimodal approach (surgery, radiation, systemic therapy) is used, and some stage IVB unresectable patients may respond to aggressive therapy. Patients with stage IVC disease should be considered for a clinical trial or hospice/palliative care, depending upon their preference.

INTRODUCTION

THE ORGANIZATION OF THESE GUIDELINES is depicted in Table 1 and directs the reader to both text and the recommendations developed from the literature reviewed. Figure 1 provides an illustrative overview of the initial management of patients suspected to have anaplastic thyroid carcinoma (ATC),

including accurate diagnosis, evaluation, and staging, followed promptly by establishing goals of care desired by the patient.

Background

Thyroid malignancies are increasing in frequency and account for 2.5% of all cancers in the United States. ATC, by far

*Robert C. Smallridge, M.D., is Chair of the American Thyroid Association Anaplastic Thyroid Cancer Guidelines Taskforce. All authors after the first author are listed in alphabetical order.

¹Mayo Clinic, Jacksonville, Florida.

²Veterans Affairs Medical Center, Lexington, Kentucky.

³University of Kentucky, Lexington, Kentucky.

⁴Princess Margaret Hospital, University Health Network, Toronto, Canada.

⁵University of Toronto, Toronto, Canada.

⁶Mayo Clinic, Rochester, Minnesota.

⁷Washington Hospital Center, Washington, District of Columbia.

⁸Endocrine Oncology Branch, National Cancer Institute, Bethesda, Maryland.

⁹Memorial Sloan-Kettering Cancer Center, New York, New York.

¹⁰University of Pittsburgh, Pittsburgh, Pennsylvania.

¹¹Program for Bioethics, University of Kentucky, Lexington, Kentucky.

¹²Ohio State University, Columbus, Ohio.

TABLE 1. ORGANIZATION OF GUIDELINES FOR THE MANAGEMENT OF PATIENTS WITH ANAPLASTIC THYROID CARCINOMA

	<i>Page</i>		<i>Page</i>
INTRODUCTION	1104	Truth-telling, patient autonomy, and beneficent care	1115
<i>Background</i>	1104	■ Recommendation 17	1115
METHODS	1107	Advance directives, surrogate decision making, and code status	1115
<i>Terms and definitions</i>	1107	■ Recommendation 18	1115
Adjuvant therapy and neoadjuvant therapy	1107	APPROACHES TO LOCOREGIONAL DISEASE	1115
Standard radiation prescription	1107	<i>Roles of surgery</i>	1115
Altered fractionation	1107	Criteria for resectability	1116
Radiotherapy dose	1108	■ Recommendation 19	1116
Concurrent chemoradiation	1108	Optimal extent of surgery and control/survival	1116
Conformal radiation	1108	■ Recommendation 20	1117
Intensity-modulated radiotherapy	1108	■ Recommendation 21	1117
Radiosurgery and stereotactic body radiotherapy (stereotactic surgeries)	1108	Need for surgery after up-front radiotherapy and/or chemotherapy in initially unresectable ATC	1117
TNM staging	1108	Incidental ATC: surgical management	1117
RECIST response	1108	■ Recommendation 22	1117
<i>Presentation of recommendations</i>	1108	■ Recommendation 23	1117
DIAGNOSIS: HISTOPATHOLOGY and DIFFERENTIAL DIAGNOSIS	1108	Surgical risk to recurrent laryngeal nerve	1117
<i>The importance of histopathology</i>	1108	■ Recommendation 24	1118
<i>Histopathological subtypes</i>	1108	Airway management and indications for tracheostomy	1118
<i>Differential diagnosis</i>	1109	■ Recommendation 25	1118
Poorly differentiated thyroid cancer	1109	Securing the airway after surgery	1118
Squamous cell thyroid cancer	1109	■ Recommendation 26	1118
Other tumors: the role of immunohistochemistry	1109	Benefits of tracheostomy	1118
■ Recommendation 1	1109	■ Recommendation 27	1118
<i>Cytology and pathology procedures</i>	1109	Surgical airway and unresectable disease	1118
Interobserver variability	1109	■ Recommendation 28	1118
FNA and core biopsy	1109	<i>Radiotherapy and systemic chemotherapy in locoregional ATC</i>	1118
■ Recommendation 2	1109	Radiotherapy after complete or near-complete (R0 or R1) resection	1118
Intraoperative frozen section and pathology consultation	1109	■ Recommendation 29	1119
■ Recommendation 3	1110	Timing and sequencing of perioperative radiation and/or systemic chemotherapy	1119
Thyroid histopathology	1110	■ Recommendation 30	1119
■ Recommendation 4	1111	■ Recommendation 31	1119
Molecular techniques	1111	Locoregional radiotherapy and/or systemic therapy in patients with unresected disease	1119
■ Recommendation 5	1111	■ Recommendation 32	1120
INITIAL EVALUATIONS	1111	■ Recommendation 33	1120
<i>Laboratory, biopsy, and imaging procedures</i>	1111	■ Recommendation 34	1120
■ Recommendation 6	1112	Radiation dose, field, and techniques (conventional, altered fractionation, IMRT)	1120
Biopsy of distant masses	1112	■ Recommendation 35	1120
■ Recommendation 7	1112	Role of systemic therapy combined with radiation	1120
<i>Timing and nature of evaluation studies</i>	1112	■ Recommendation 36	1121
■ Recommendation 8	1112	<i>Supportive care during active therapy</i>	1122
Airway and vocal cord assessment	1112	Airway management	1122
■ Recommendation 9	1112	■ Recommendation 37	1122
Staging and order of therapies	1112	Maintenance of nutrition (PEG/feeding tube)	1122
■ Recommendation 10	1113	■ Recommendation 38	1122
Indications for neoadjuvant therapy	1113	■ Recommendation 39	1122
■ Recommendation 11	1113	Parenteral nutrition in perioperative management	1122
<i>Postdiagnostic care of ATC</i>	1113	■ Recommendation 40	1122
■ Recommendation 12	1113	Growth factor support during chemoradiation therapy	1122
<i>Prognostic factors</i>	1113	■ Recommendation 41	1122
■ Recommendation 13	1114		
ESTABLISHING TREATMENT GOALS	1114		
<i>Treatment and care goals</i>	1114		
Advanced care planning and goals of care	1114		
■ Recommendation 14	1114		
Decision-making capacity and informed consent	1114		
■ Recommendation 15	1114		
Surrogate decision making	1114		
■ Recommendation 16	1115		

(continued)

TABLE 1. (CONTINUED)

	Page		Page
APPROACHES TO ADVANCED METASTATIC DISEASE (STAGE IVC)	1123	<i>Utility of cryoablation and selective embolization</i>	1128
<i>Defining therapeutic goals, expected/possible adverse events, appropriate expectations, and limits of care</i>	1123	■ Recommendation 54	1128
<i>Timing of systemic therapies</i>	1123	<i>Approach to thrombosis and/or tumor invasion into vasculature</i>	1128
■ Recommendation 42	1123	■ Recommendation 55	1128
<i>Approaches to systemic disease (cytotoxic)</i>	1123	■ Recommendation 56	1128
Taxanes	1123	■ Recommendation 57	1128
Anthracyclines and platins	1123	PALLIATIVE CARE AND HOSPICE	1128
First-line therapy	1124	<i>Definition of a palliative care service</i>	1129
Second-line or salvage therapy	1124	When to involve palliative care in ATC	1129
<i>Approaches to systemic disease (novel or investigational)</i>	1124	When to involve hospice care in ATC	1129
■ Recommendation 43	1125	Working effectively with a palliative care or hospice care team	1129
■ Recommendation 44	1125	■ Recommendation 58	1129
■ Recommendation 45	1125	■ Recommendation 59	1129
■ Recommendation 46	1125	SURVEILLANCE AND LONG-TERM MONITORING	1129
<i>Systemic therapy: what is next?</i>	1125	<i>Surveillance after clinical remission</i>	1130
<i>Approaches to brain metastases</i>	1125	■ Recommendation 60	1130
■ Recommendation 47	1125	■ Recommendation 61	1131
■ Recommendation 48	1125	■ Recommendation 62	1131
■ Recommendation 49	1126	■ Recommendation 63	1131
■ Recommendation 50	1126	<i>Restaging of patients with persistent metastatic disease</i>	1131
<i>Approaches to bone metastases</i>	1126	■ Recommendation 64	1131
■ Recommendation 51	1127	■ Recommendation 65	1131
■ Recommendation 52	1127	SUMMARY	1131
■ Recommendation 53	1127		
<i>Approaches to other sites of metastases</i>	1127		

ATC, anaplastic thyroid cancer; FNA, fine-needle aspiration; IMRT, intensity-modulated radiotherapy; PEG, percutaneous gastrostomy; RECIST, Response Evaluation Criteria in Solid Tumors.

the most deadly of thyroid-derived tumors, fortunately accounts for but a small percentage. In the United States, ATC is responsible for 1.7% of all thyroid cancers, while geographically the prevalence ranges from 1.3% to 9.8% (median=3.6%) (1). In several countries the prevalence of ATC has decreased dramatically, due in part to increased dietary iodine and better management of differentiated thyroid cancer (DTC) (2,3).

Unlike DTC, which is derived from follicular thyroid cells, and medullary thyroid cancer (MTC), which are frequently cured or associated with prolonged survival, ATC patients have a median survival of 5 months and a 20% 1-year survival

rate (1). All patients are classified by the American Joint Committee on Cancer (AJCC) TNM system as stage IV (A, B, or C) at presentation, and counseling and establishing a management plan must be accomplished quickly. While all thyroid cancer patients require a multidisciplinary team of specialists for optimal care, the coordinating physician is frequently an endocrinologist who has established a long-standing relationship with the patient who has DTC or MTC. In contrast, the sudden onset and explosive course of ATC necessitates immediate involvement by surgeons, radiation and medical oncologists, and palliative care teams.

The American Thyroid Association (ATA) has a history of supporting the development of guidelines for the care of patients with thyroid disease.* This includes several guidelines for management of DTC (4–6) and recent first MTC guidelines (7). No such ATA guidelines exist for management of patients with ATC. The Latin American Thyroid Society has also published recommendations for DTC management (8). Other organizations have made recommendations for patients with ATC. The National Comprehensive Cancer Network devotes 37 pages to treating and following DTC patients but only three pages for ATC (9). The American Association of Clinical Endocrinologists guidelines for thyroid cancer discuss ATC management in less than one page (10).

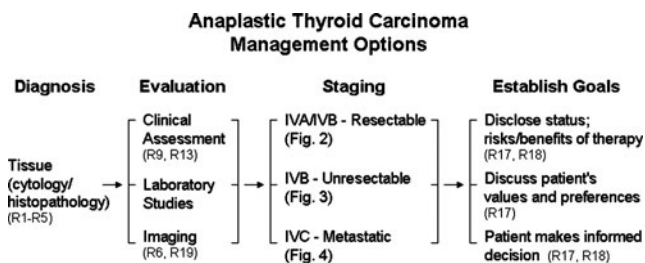


FIG. 1. An overview of management options for patients with anaplastic thyroid carcinoma includes confirming the diagnosis, thoroughly evaluating the patient to permit accurate staging of the disease, and subsequently establishing treatment goals according to the patient's wishes. Recommendations and figures that pertain to each topic are noted in this and subsequent figures.

*For information provided by the ATA on guideline publications they approve and endorse, see the Supplementary Data, available online at www.liebertpub.com/thy

Accordingly, the ATA Board of Directors requested that an independent task force, which authored this publication, develop a more comprehensive set of guidelines to assist practitioners in the management of critically ill patients with ATC. The authors include physicians who specialize in endocrinology, endocrine surgery, head/neck surgery, nuclear medicine, radiation oncology, medical oncology, pathology, and bioethics. The medical opinions expressed in these guidelines are those of the authors.

The final document was approved by the ATA Board of Directors, and was officially endorsed by (in alphabetical order) the American Academy of Otolaryngology—Head and Neck Surgery (AAO-HNS), American Association of Clinical Endocrinologists (AACE), American Head and Neck Society (AHNS), Italian Association of Clinical Endocrinologists (AME), Asia and Oceania Thyroid Association (AOTA), The Endocrine Society, European Thyroid Association (ETA), International Association of Endocrine Surgeons (IAES), Latin American Thyroid Society (LATS), and the Brazilian Society of Head and Neck Surgery (SBCCP).

METHODS

In preparing these guidelines, we developed a list of questions covering the areas of diagnosis, initial evaluation, establishing treatment goals, approaches to locoregional disease, approaches to advanced/metastatic disease, palliative care/hospice, and surveillance and long-term monitoring. To maximize our deliberations we developed preliminary recommendations and solicited input from the ATA Board of Directors and members of the ATA by posting them on the members-only section of the ATA website (www.thyroid.org). All responses were from ATA members. Final recommendations, the strength of the recommendation, and the quality of the evidence were arrived at by consensus of the authors.

To identify all literature that might assist in preparing this document, a PubMed search of the terms “anaplastic thyroid cancer,” “anaplastic thyroid carcinoma,” and “anaplastic thyroid” was performed. A total of 2157 articles were identified. A search of “ATC and randomized clinical trials” was also performed and yielded no publications.

To rank the strength of each recommendation and the quality of the evidence supporting that recommendation, the Taskforce used the criteria described in Table 2. These criteria were adapted from the Clinical Guidelines Committee of the American College of Physicians (11), which in turn were developed by the Grading of Recommendations Assessment, Development and Evaluation workgroup (12). Given the rarity of ATC and lack of funding to support prospective trials, the types of publications are mostly low-quality. However, the authors consider that they were frequently able to make strong recommendations.

For ATC, the extent of surgical resection has been implicated as a prognostic factor by many authors. Therefore, the AJCC Cancer Staging Manual (7th edition) Residual Tumor (R) Classification was used to assess surgical effects on outcomes across the studies reviewed (Table 3) (12a).

TABLE 2. CRITERIA USED IN RANKING STRENGTH OF RECOMMENDATIONS AND QUALITY OF EVIDENCE

<i>Strength of recommendation</i>	
Strong	Benefits clearly outweigh risks and burden, <i>or</i> risks and burden clearly outweigh benefits
Weak	Benefits finely balanced with risks and burden
None	Insufficient evidence to determine net benefits or risks
<i>Quality of evidence</i>	
High	Requires one or more randomized, controlled trials without important limitations, or overwhelming evidence from observational studies
Moderate	Derived from trials with important limitations, or exceptionally strong observational studies
Low	Supported only by observational studies or case series
Insufficient for grading	Evidence is lacking, of poor quality, or conflicting

Adapted from Qaseem *et al.* (11).

Terms and definitions

Adjuvant therapy and neoadjuvant therapy. Radiation, systemic therapy, or the combination given *after* surgery with curative intention is referred to as *adjuvant therapy*. Radiation, systemic therapy, or the combination given *before* surgery with curative intention is referred to as *neoadjuvant therapy*.

Standard radiation prescription. The unit dose of radiation is the gray (Gy); some prescriptions are given in centigray (1 Gy = 100 cGy). A radiation prescription describes the total dose of radiation to be given, the number of fractions (number of daily treatments), the size of each daily treatment, and the overall length of the treatment course. The usual daily fraction size is 1.8 or 2 Gy. A standard prescription would be, for instance, 66 Gy over 6.5 weeks, given as 33 daily fractions of 2 Gy per day, 5 days a week.

Altered fractionation. Altered fractionation implies either a larger number of fractions (*hyperfractionated*), or a smaller number of fractions (*hypofractionated*), or a shorter overall treatment time (*accelerated*). By use of hyperfractionated treatment, more than one daily fraction may be given, enabling the prescription to be given over a shorter treatment time (*accelerated hyperfractionated radiotherapy*). In a

TABLE 3. RESIDUAL TUMOR (R) CLASSIFICATION

R0 = no residual tumor
R1 = microscopic residual tumor
R2 = macroscopic residual tumor
RX = presence of residual tumor cannot be assessed

Source: Edge *et al.* (12a), page 23.

rapidly growing tumor such as ATC, accelerating the treatment has the potential to overcome any tumor growth that may occur over the radiotherapy treatment course. By giving multiple small fractions, the toxicity may also be reduced. An example of an accelerated hyperfractionated prescription would be 60 Gy over 4 weeks given as 40 twice daily fractions of 1.5 Gy, 5 days a week.

Radiotherapy dose. There are many different potential radiation prescription doses; for the purpose of this report they have been grouped as definitive or palliative. **Definitive radiotherapy** is high-dose radiation given with or without concurrent chemotherapy, with the intent of maximizing the chance of long-term local control. Examples range from 50 Gy in 20 fractions, 2.5 Gy per fraction over 4 weeks at the low end, to 70 Gy in 35 fractions, 2 Gy per fraction over 7 weeks at the high end. **Palliative radiotherapy** is lower dose radiotherapy given over a shorter time period with the aim of improving local symptoms. It may be directed to the primary tumor or to metastases. Typical examples could be 20 Gy in five fractions, 4 Gy per fraction over 1 week and 30 Gy in 10 fractions, 3 Gy per fraction over 2 weeks.

Concurrent chemoradiation. Some chemotherapeutic agents when given concurrently with radiation can potentiate the antitumor effects of radiation and thereby act as "radiation sensitizers." This therapeutic advantage may be at the cost of increased toxicity, and in some regimes a reduction of the radiation dose may be required. The aim of chemotherapy given concurrently with radiation is to increase the chance of local control of the tumor. The dose of chemotherapy when given with radiotherapy may be insufficient to have a systemic effect on potential or known metastatic disease.

Conformal radiation. In conformal radiotherapy the radiation volume treated is tailored to and "conforms" to the shape of the tumor. The toxicity of radiation to the surrounding normal tissues is thereby reduced.

Intensity-modulated radiotherapy. By modulation of the intensity of the radiation fields as well as shape of the fields, the radiation can be made more conformal (tailored), thereby reducing toxicity to normal structures further and potentially enabling a higher radiation dose to be given to the tumor areas.

Radiosurgery and stereotactic body radiotherapy (stereotactic surgeries). Radiosurgery and stereotactic body radiotherapy is highly conformal/focused radiation that allows a single large fraction of radiation to be given. **Stereotactic radiosurgery** usually refers to radiosurgery to the brain (e.g., Gamma Knife). **Stereotactic body radiosurgery** usually refers to radiosurgery to parts of the body other than to the brain (e.g., CyberKnife, X-Knife), and **stereotactic body radiotherapy** usually refers to highly conformal radiotherapy given in 3 to 10 fractions.

TNM staging. All ATCs are stage IV. IVA lesions are intrathyroidal (T4a), and N0, M0 (no distant metastases). In stage IVB, the primary tumor has gross extrathyroidal extension, any N, M0. Stage IVC patients have distant metastases.

RECIST response. Response Evaluation Criteria in Solid Tumors (RECIST) are used to assess objectively the effects of

systemic therapy. After determining the baseline diameters of index lesions with computerized tomography (CT) scans, follow-up measurements are determined at defined intervals. A complete response (CR) means disappearance of all lesions, a partial response (PR) is at least a 30% reduction in size, progressive disease is a 20% or greater increase, and stable disease refers to tumors not reaching criteria for either PR or progressive disease.

Presentation of recommendations

In line with and echoing some of the official policy of the ATA, our recommendations are not inclusive of all proper approaches or methods, nor exclusive of others. They do not establish a standard of care and specific outcomes are not guaranteed. We recommend that treatment decisions be based on independent judgment of health care providers and each patient's individual circumstances. Our guideline recommendations are not intended to take the place of physician judgment in diagnosing and treating particular patients. We expect those who use this guideline to do so as an aid in clinical decision-making, with full consideration of each patient's individuality in terms of history and physical traits.

DIAGNOSIS: HISTOPATHOLOGY AND DIFFERENTIAL DIAGNOSIS

The importance of histopathology

The diagnosis of ATC can often be suspected clinically, but the large differential diagnosis, reviewed below, necessitates tissue evaluation to exclude other treatable entities with better prognoses. The diagnosis of thyroid pathology involves correlation of clinical, biochemical, radiographic, and morphological features of the individual case. This is particularly important for ATC (13).

ATCs exhibit wide variations in appearance with several morphologic patterns recognized and many tumors manifesting a mixed morphology (14,15). A common morphologic presentation, and one that is most easily recognized as an anaplastic carcinoma of thyroid, is that of the biphasic spindle and giant cell tumor. Other tumors are dominated by bizarre malignant giant cells, and still others may show a more pure population of spindle and squamoid cells (16). All variations of anaplastic carcinoma of the thyroid are highly proliferative with numerous mitotic figures and atypical mitoses (17). There is usually extensive necrosis, and in some cases the necrosis may be so widespread that the only viable tumor is preserved around blood vessels. Inflammatory infiltrates are frequently seen with the necrosis. Osteoclast-like giant cells may be present and have been shown by immunohistochemical studies to be of the monocytic/histiocytic lineage (18,19). Neoplastic bone and cartilage may also be identified.

Histopathological subtypes

ATC has three main histological growth patterns: spindle cell pattern, pleomorphic giant cell pattern, and squamoid pattern. One of these patterns may predominate in a given tumor, or the tumor may show a mixture of two or three different patterns (14,20–22). Rare histological variants of anaplastic carcinoma include the paucicellular variant and the rhabdoid variant (23–31). The histological subtypes and

variants of anaplastic carcinoma have no known prognostic significance, with the possible exception of the paucicellular variant, which in some studies was found to affect younger patients and have a more indolent course (23,25). A variant known in the past as small cell variant of anaplastic carcinoma is practically nonexistent at the present time, since most of these tumors are currently appropriately classified as lymphoma, medullary carcinoma, or poorly differentiated thyroid carcinoma (14,32,33).

Differential diagnosis

Poorly differentiated thyroid cancer. Thyroid carcinomas can exhibit an entire spectrum of differentiation. Poorly differentiated carcinoma is intermediate on the spectrum between well-differentiated and anaplastic carcinoma and may represent a transition form (34,35). The majority of these lesions have an architectural growth pattern that is characterized by large, well-defined solid nests, an appearance that mimics neuroendocrine tumors, hence the terminology “insular” carcinoma. Other tumors have trabecular growth patterns. The tumor cells are usually small and uniform in size; in contrast to anaplastic carcinomas there is little pleomorphism, and no bizarre, giant, or multinucleated cells are found. There is mitotic activity with three or more mitoses per 10 high power fields (36,37), which is less than that seen in anaplastic carcinomas. Tumor necrosis is usually identified as single cell necrosis or small well-defined necrotic foci in the center of cell nests rather than the large areas of geographic necrosis that are characteristic of anaplastic carcinoma. Preservation of immunohistochemical markers of epithelial and thyroid differentiation, such as thyroglobulin (Tg) and thyroid transcription factor 1 (TTF1), in poorly differentiated carcinoma can help to distinguish it from anaplastic carcinoma.

Squamous cell thyroid cancer. ATC with a predominant squamoid growth pattern may resemble squamous carcinoma morphologically and immunohistochemically (14,15,18,38,39). Primary squamous cell carcinoma of the thyroid is exceedingly rare (40–42), accounting for less than 1% of thyroid malignancies. It can be impossible to distinguish these lesions, and their clinical behavior is not distinct (43). The presence of an adjacent well-differentiated component of papillary or follicular carcinoma or the presence of thyroid-specific molecular events provides evidence that a lesion is ATC (16,44,45). The morphology of primary squamous carcinoma of the thyroid is not distinctive, and its appearance is identical to squamous carcinoma arising elsewhere; therefore, whenever possible an invasive laryngeal or metastatic squamous carcinoma must be excluded prior to making the diagnosis of a primary squamous carcinoma of the thyroid.

Other tumors: the role of immunohistochemistry. On fine-needle aspiration (FNA) or core biopsy, some thyroid tumors present a variety of differential diagnostic possibilities depending on the predominant morphologic pattern present in the sample. When the tumor presents in the form of a poorly differentiated large B cell carcinoma, the differential diagnosis includes large cell lymphoma (both diffuse large cell lymphoma and anaplastic large cell lymphoma), medullary carcinoma, direct extension of a laryngeal carcinoma, metastatic carcinoma

(18), metastatic melanoma, and ATC. When the spindle cell morphology dominates or the tumor appears biphasic with both epithelial and spindle cell components, the differential diagnosis once again includes medullary carcinoma, metastatic carcinoma (in particular a sarcomatoid renal primary), melanoma, and ATC, but now must include sarcomas (both primary and metastatic) as well as involvement of the thyroid by a primary laryngeal sarcomatoid squamous carcinoma. Occasionally infectious and inflammatory lesions can mimic anaplastic carcinoma (46,47). Resolution of these diagnostic possibilities requires careful attention to the morphology, combined with special stains or immunohistochemical studies (48–50) (see Table 4) and clinical information to arrive at the conclusion that the poorly differentiated malignancy is an ATC.

RECOMMENDATION 1

Morphologic diagnosis with appropriate immunostaining as relevant is mandatory to exclude other less aggressive and treatable entities that can mimic ATC.

Strength of Recommendation: Strong

Quality of Evidence: Moderate

Cytology and pathology procedures

Interobserver variability. How consistently do pathologists make the diagnosis of ATC on the same sample? There are no data on interobserver variation in the diagnosis of ATC. However, this diagnosis is often one of “exclusion” when there is no evidence of other lesions that can mimic ATC. As with any result of an interpretive nature, accuracy may differ in the hands of experts who have more experience with this disease.

FNA and core biopsy. Morphological diagnosis of FNA biopsy may be diagnostic (51–54), but FNA may not always yield diagnostic material. In cases in which the limited sampling of FNA biopsy yields mainly necrotic or inflamed tissue, there may be a need for core biopsy or open biopsy. There is no cytologic description of the paucicellular variant of ATC, likely due to an inability to obtain diagnostic tissue in this setting (13); core biopsy or open biopsy is usually required for this diagnosis.

RECOMMENDATION 2

FNA cytology or core biopsy should play a role in the preoperative diagnosis of ATC. In cases in which the limited sampling of FNA or core biopsy yields material that is nondiagnostic, open biopsy should be performed to obtain diagnostic tissue.

Strength of Recommendation: Strong

Quality of Evidence: Low

Intraoperative frozen section and pathology consultation. Intraoperative consultation is used as a method of providing rapid diagnosis to assist in determining the ongoing operative extent and approach. Appropriate utilization of frozen sections should be limited to situations that fulfill three criteria. These are (i) the result of the intraoperative consultation should alter the surgical procedure, (ii) the information provided by the intraoperative consultation should not be available by other preoperative tests, and (iii) the information required must be realistically and practically

TABLE 4. IMMUNOHISTOCHEMICAL MARKERS USEFUL FOR THE DIAGNOSIS OF ANAPLASTIC THYROID CANCER

<i>Immunohistochemical marker</i>	<i>DTC</i>	<i>MTC</i>	<i>ATC</i>	<i>SCC</i>	<i>Lymphoma</i>
Pankeratin (AE1/AE3)	+	+	+/-	+	- ^a
High molecular weight keratins	+ (PTC) - (FTC)	-	-/+	+	-
TTF-1	+	+/-	-/+	-	-
PAX8	+	+/-	+/-	-	+/- ^b
Thyroglobulin	+	-	-	-	-
Synaptophysin	-	+	-	-	-
Chromogranin	-	+	-	-	-
Calcitonin	-	+	-	-	-
CEA	-	+	-	-	-
P53	- (rare +)	-	+	+/-	+/-
E-cadherin	+	-	-	+	-
B-catenin	membranous		nuclear or -		+/- (nuclear)
CD45					+

^aPlasmablastic lymphoma, anaplastic large cell lymphoma, and very rarely some diffuse large B cell lymphomas can express cytokeratin that is detected by AE1/AE3 cytokeratin monoclonal antibodies.

^bPAX8 was detected by immunohistochemistry in normal B cells, but was not studied in lymphoma. It is very likely that various lymphomas express PAX8.

ATC, anaplastic thyroid carcinoma; CD45, protein tyrosine phosphatase receptor type C; CEA, carcinoembryonic antigen; DTC, differentiated thyroid carcinoma; FTC, follicular thyroid carcinoma; MTC, medullary thyroid carcinoma; P53, cellular tumor antigen p53 or tumor protein p53; PAX8, paired box protein Pax 8 or paired box 8; PTC, papillary thyroid carcinoma; SCC, squamous cell carcinoma; TTF-1, thyroid transcription factor 1; +, positive; -, negative; +/-, usually positive, often negative; -/+, usually negative, may be positive.

obtainable by pathologists performing the intraoperative consultation.

These three criteria are not frequently fulfilled in the diagnosis of ATC. Usually, the diagnosis is anticipated prior to surgery for open biopsy, and the procedure is being performed primarily to obtain tissue for diagnosis. Since freezing of tissue compromises morphology and may preclude accurate and definitive diagnosis, it is not recommended as a routine procedure. However, there may be indications for intraoperative evaluation in two scenarios.

If preoperative biopsies yield mainly necrotic tissue, the surgeon's objective in performing a biopsy is to obtain viable diagnostic material. Confirmation of such may entail intraoperative evaluation of a small piece of tissue to ensure that the remainder of the specimen is appropriate for further studies. This might be done by frozen section, but may be equally as productive when tissue is used to make "touch preparations" for cytologic assessment, thereby not freezing the tissue and altering its morphology. Involvement of the pathologist at this stage is also helpful to ensure that samples are correctly collected for other nonroutine testing such as microbiological examination to exclude infectious disorders that can mimic anaplastic carcinoma, collection of material for flow cytometry if a hematological malignancy is in the differential diagnosis, or snap freezing material for molecular diagnostics. The involvement of the pathologist for any of these procedures will not yield a diagnosis at the time of intraoperative consultation but should result in a more thorough and accurate final report.

The second situation in which intraoperative pathologist consultation may prove valuable in the diagnosis of ATC arises when the diagnosis is not suspected preoperatively, but is encountered unexpectedly. This rare occurrence may be faced when a patient is thought to have a differentiated thyroid malignancy, even after biopsy has confirmed the diagnosis, but the surgeon encounters unusual features during the operative procedure. In this situation, a frozen section may be

used to confirm dedifferentiation of a lesion, and the result may alter the surgical approach.

■ RECOMMENDATION 3

Whenever possible, a definitive diagnosis should be obtained prior to surgery. Intraoperative pathology consultation can be used to define the adequacy of the resected tissue for diagnostic evaluation or to identify ATC in a patient when that diagnosis was not anticipated preoperatively. Intraoperative pathology consultation is not usually appropriate for definitive diagnosis.

Strength of Recommendation: Strong

Quality of Evidence: Low

Thyroid histopathology. The indications for thyroidectomy are discussed later in this article. Histologic examination of a thyroidectomy specimen provides additional material to examine the extent of disease and to identify additional coexisting differentiated components of the disease. ATC often originates in an abnormal thyroid gland; a history of goiter is reported in >80% of cases (55,56), and the reported association between well-differentiated thyroid carcinoma and ATC ranges from 7% to 89% of cases. The lower figures are likely underestimates, attributable to failure to detect a well-differentiated component due to inadequate sampling (14,15,24,35,55-57). The association of papillary carcinoma, particularly the more aggressive tall cell variant, with anaplastic tumors has also been described (16,35,56).

In many cases (20%-90%), histological examination of ATC identifies a coexisting well-differentiated carcinoma, or patients have a history of previously resected well-differentiated or poorly differentiated thyroid carcinoma (14,15,24,26, 55,58,59). This supports the notion that many ATCs develop by dedifferentiation of a preexisting well-differentiated thyroid carcinoma. Well-differentiated papillary carcinoma, often the tall cell variant, is the most common coexistent carcinoma, followed in frequency by follicular carcinoma

of conventional type or oncocytic (Hürthle cell) type (16, 22,35,60). An adjacent component of poorly differentiated thyroid carcinoma may also be seen. In some anaplastic carcinomas, no well-differentiated or poorly differentiated cancer component is found on histological examination. The presence of coexisting well-differentiated or poorly differentiated carcinoma may be substantiated by finding preserved immunohistochemical staining for Tg, TTF1, and paired box protein Pax 8 (PAX8) in better differentiated areas (22). The finding of coexisting or preexisting well-differentiated or poorly differentiated carcinoma is helpful in establishing a definitive diagnosis of ATC by ruling out metastatic carcinoma and nonepithelial malignancy. The proportion of anaplastic carcinoma in a given tumor may influence prognosis. Although data are limited, survival is likely to be more prolonged in cases in which anaplastic carcinoma comprises only a small component of an otherwise well-differentiated papillary or follicular thyroid carcinoma (55,61,62).

■ RECOMMENDATION 4

Pathological evaluation should provide information on the proportion of tumor that comprises ATC and coexistent well-differentiated or poorly differentiated thyroid carcinoma, which may affect prognosis and guide management.

Strength of Recommendation: Strong

Quality of Evidence: Low

Molecular techniques. ATCs are typically aneuploid and have a complex karyotype with multiple numerical and structural chromosomal abnormalities (63–69). Loss of heterozygosity at multiple chromosomal regions is very common (70–73). A progressive accumulation of chromosomal alterations can be observed when comparing well-differentiated carcinomas with poorly differentiated carcinomas and anaplastic carcinomas, which supports the multistep dedifferentiation process (69,74). Most common somatic mutations found in ATCs are in the *TP53* and *β-catenin* (*CTNNB1*) genes (75–80). These mutations rarely occur in well-differentiated thyroid cancer. Other mutations, such as *BRAF* and *RAS*, are common in both well-differentiated thyroid cancer and ATCs and are likely to be early events in thyroid carcinogenesis that may predispose to tumor dedifferentiation (60,81). *PIK3CA* and *PTEN* gene mutations also occur in both well-differentiated thyroid cancer and ATCs. Papillary thyroid carcinomas carrying *RET/PTC3* rearrangement may also be prone to dedifferentiation (82,83). Other rearrangements found in well-differentiated papillary and follicular carcinomas, such as *RET/PTC1* and *PAX8/PPAR γ* , have not been detected in anaplastic carcinomas, but this may be due to technical limitations since the studies have been based on RNA expression that may be lost with dedifferentiation. Profound alterations in gene expression, microRNA, and protein composition are also found in ATCs (84). These molecular alterations provide potential therapeutic targets for novel therapies that may be clinically relevant in the future. Molecular markers have also been studied as candidate prognostic factors; it appears that higher urokinase-type plasminogen activator receptor (u-PAR) expression and protein formation may be associated with increased mortality (85). Currently, molecular techniques do not play a significant role in the diagnosis of ATC or provide guidance for patient management, although they

may occasionally be used to aid the diagnosis. Finding a *BRAF* or *RAS* mutation in a small biopsy sample would generally favor thyroid origin of an undifferentiated tumor, but these mutations are not specific for thyroid carcinomas and may occur in other malignant tumors. Detection of *RET/PTC* and *PAX8/PPAR γ* expression is fairly specific for thyroid cell origin; however, it is rarely found in ATC (79). Although *TP53* and *β-catenin* mutations may occasionally be seen in poorly differentiated carcinomas, their presence would suggest tumor dedifferentiation.

■ RECOMMENDATION 5

Molecular studies based on DNA/RNA analysis are not currently required for diagnosis and management of patients with ATC.

Strength of Recommendation: Strong

Quality of Evidence: Moderate

INITIAL EVALUATIONS

Laboratory, biopsy, and imaging procedures

When a patient presents with a thyroid mass or metastatic lesion that has been characterized as ATC through appropriate cytological and/or histological assessment, there are a number of preoperative staging procedures that are likely to be of value. These consist of a physical examination and laboratory studies to appropriately characterize the physiological status of the patient and provide baseline parameters for further medical care issues, as well as radiological studies to determine the extent of disease for tumor staging and determine the best medical and/or surgical therapy.

Requisite laboratory studies include a complete blood count and differential to evaluate for anemia, assess adequacy of platelets, and to discern any underlying leukocytosis suggestive of active infection (86) or diminished white blood cell components indicating immunodeficiency. It should be noted that rare ATC patients present with marked leukocytosis consequent to tumor secretion of lymphokines (87,88). Blood chemistry evaluation could include: electrolytes, serum urea nitrogen, creatinine, glucose, and liver function tests. Free thyroxine and thyrotropin should be assessed because large tumor masses may have compromised thyroid function, and some cases of ATC are associated with significant thyrotoxicosis (89,90). Calcium and phosphorus should be measured because tumor invasion may compromise parathyroid function, and unusual ATC cases can present with humoral hypercalcemia of malignancy (91). Since ATC is most common in elderly patients, often with diminished nutrition, ionized calcium provides superior assessment of calcium status (92), although calculations involving serum protein levels and total calcium values may be useful when ionized calcium values are not available (93). Coagulation studies, prothrombin time and activated partial thromboplastin time, should also be obtained. Considering the technical difficulties of surgical resection for invasive ATC and the likely need for blood transfusion, it is reasonable to provide a preoperative blood sample for type and cross-match rather than just utilizing a type-and-hold approach if surgical resection is being planned.

It is axiomatic that adjunctive preoperative radiological studies should not delay urgent therapeutic intervention and that required radiologic tests should be scheduled expeditiously. Cross-sectional imaging of the neck and chest should

be performed to assess the extent of disease and to plan any subsequent surgery and/or radiation therapy (94). A high resolution ultrasound of the neck should be obtained because it is able to provide rapid evaluation of the primary thyroid tumor and to assess for involvement of the central and lateral lymph node basins and to assist in evaluating airway patency. If accessible, positron emission tomography (PET), utilizing ^{18}F -fluorodeoxyglucose (^{18}F FDG) and fused to a coincident CT scan (brain to pelvis), is particularly valuable in evaluating metastatic sites (95–98). This may be useful in the context of distinguishing ATC metastases from coincident DTC metastases due to the greater glucose transport of ATC cells from enhanced expression of the Glut-1 glucose transporter with resultant significantly elevated modified standard uptake values (increased uptake of ^{18}F FDG) (99). Cross-sectional imaging of the neck and chest with magnetic resonance imaging (MRI) and/or CT scan is also imperative to determine the presence of regional disease and exclude distant metastasis. For better evaluation of the extent of disease, CT scan with intravenous contrast will be helpful. Alternatively, MRI using gadolinium contrast can evaluate the neck and superior mediastinum (100).

■ RECOMMENDATION 6

Adjunctive preoperative radiological tumor staging should not delay therapy and should make use of appropriate cross-sectional imaging including neck ultrasound, CT scans or MRI (for the neck and chest), and PET/CT fusion scans.

Strength of Recommendation: Strong
Quality of Evidence: Moderate

Biopsy of distant masses. It is common for ATC and DTC to coexist in the same patient (24,55) because ATC usually arises by dedifferentiation of preexisting DTC. In this context, it may be necessary to attempt to distinguish macroscopic distant metastases of ATC from those of DTC, because of the significant differences in prognostic implication and because it could alter the therapeutic approach. Likewise, ATC may be diagnosed in patients with separate cancers (previously diagnosed or not) such as primary lung carcinomas, metastatic prostate cancers, or metastatic breast cancers. Under such circumstances, therapeutic modalities vary considerably depending upon the proper tumor diagnosis.

There may be some clinical clues that could prove informative. PET/CT fusion studies may be able to distinguish hypermetabolic ATC metastases, which have increased uptake of ^{18}F FDG, from more indolent metastases typically observed in DTC or some other cancers. Likewise, severely elevated tumor markers (i.e., prostate-specific antigen for prostate cancer, Tg for DTC) may suggest the need to distinguish and characterize distant metastases. Fine-needle biopsy of distant metastatic sites, along with appropriate immunohistochemical analysis, can be used to resolve such questions.

Although it is important to properly characterize the etiology of metastatic tumor sites, it would be unusual for this knowledge to have a significant effect upon the planning or implementation of primary surgery for ATC. For this reason, in most circumstances primary surgery should not be delayed to biopsy distant metastases. Such biopsies may be pursued after primary surgery is completed in the rare circumstances when such questions arise. It is not expected that this will be needed in most cases of ATC.

■ RECOMMENDATION 7

Primary management of ATC should not be delayed in order to biopsy tumors at distant sites. If clinically indicated, such biopsies could be performed after completion of primary surgery.

Strength of Recommendation: Weak
Quality of Evidence: Low

Timing and nature of evaluation studies

In the assessment of a rapidly growing neck mass, necessary preoperative evaluations must be completed quickly. All initial staging procedures should be expedited by the treating physician and should not be relegated to any schedule that delays treatment. It is critical that preoperative medical and anesthesia assessments be accomplished in the briefest time if required.

■ RECOMMENDATION 8

All critical appointments and assessments that are required prior to primary treatment of ATC should be prioritized and completed as rapidly as possible.

Strength of Recommendation: Strong
Quality of Evidence: Low

Airway and vocal cord assessment. Vocal cord paralysis is quite common in patients with ATC, as compared with those with well-differentiated thyroid cancer. Because of the rapid increase in tumor size, the patient may present with obvious hoarseness of voice, raising the question of vocal cord mobility. The best way to evaluate vocal cord mobility is laryngeal evaluation, which can easily be performed in the office with mirror or fiber optic laryngoscopy. Most patients will present with one paralyzed vocal cord and an adequate airway. The endolaryngeal mucosa is generally normal. The fiber optic laryngoscopy will also help to evaluate whether there is direct involvement of the tumor, either in the larynx or the upper trachea. In patients with airway invasion on laryngoscopy, a bronchoscopy to evaluate the trachea is helpful to determine extent of disease and resectability.

■ RECOMMENDATION 9

Every patient should undergo initial evaluation of the vocal cords. The best way to evaluate the vocal cords is with fiber optic laryngoscopy; however, mirror examination may be acceptable. Fiber optic laryngoscopy will also help to assess the opposite vocal cord, mobility of the vocal cord, and endolaryngeal pathology and whether there is any extension of disease in the subglottic or upper tracheal area.

Strength of Recommendation: Strong
Quality of Evidence: Low

Staging and order of therapies. In the context of a rapidly growing neck mass that may compromise the airway and cause thoracic outlet syndrome, there are very few findings from staging that could delay planned local therapies. For example, impending neurological crisis, either from a growing brain metastasis or vertebral metastases that compromise the spinal cord, would constitute sufficient cause for delaying primary thyroid site surgery until after emergent surgical or radio-surgical care is rendered. Likewise, pulmonary hemorrhage from metastatic disease may demand priority if life threatening.

Preoperative medical assessment may indicate significant surgical risk, particularly in the context of severe ischemic cardiac or cerebrovascular disease. Considering the almost certain lethality of unresected primary ATC, it may be considered reasonable to proceed with surgery in situations that would preclude elective procedures.

■ RECOMMENDATION 10

Only imminently threatening disease elsewhere (e.g., brain or spine metastases or pulmonary hemorrhage) should prevent primary surgical management of neck disease if achievable.

Strength of Recommendation: Strong

Quality of Evidence: Low

Indications for neoadjuvant therapy. More than 80% of ATC patients present with extensively invasive primary tumors (101). Careful radiological assessment of tumor involvement in the visceral compartment, nearby vascular structures, and posterior paraspinous structures may reveal significant obstacles to successful primary surgery. This is because a 69% rate of tracheal invasion, 55% rate of esophageal invasion, and 39% rate of carotid artery involvement have been reported (102). Endoscopic evaluation of hypopharynx, esophagus, larynx, and trachea may be needed to supplement radiographic studies. The aggressiveness of the operative resection should be considered in the context of morbidities that may occur from resecting adjacent involved structures. Extensive tumor involvement in the thoracic inlet and upper mediastinum may presage involvement of mediastinal vascular structures that warrant emergent sternotomy to control hemorrhage. Approximately 38% of primary thyroidectomies for ATC require extended resections (2). Ultimately, preoperative staging and assessment of local tumor extent are balanced against the experience, judgment, and technical expertise of the surgeon to determine whether a primary tumor resection should be attempted with acceptable morbidity and risk. Thus, the definition of *unresectable* can vary among different surgeons.

If a primary tumor is deemed unresectable, then there are alternative approaches. Full or partial course external beam radiotherapy may be followed by primary surgical resection, then completion of radiotherapy if there had been a partial course. This can be as efficacious as initial primary resection (103). Likewise, neoadjuvant chemotherapy (104) may prove effective in permitting delayed primary resection in similar circumstances.

■ RECOMMENDATION 11

If preoperative staging and primary tumor assessment define the tumor extent as precluding safe or effective surgical resection, neoadjuvant external beam radiotherapy and/or chemotherapy should be considered to permit delayed primary surgical resection.

Strength of Recommendation: Strong

Quality of Evidence: Moderate

Postdiagnostic care of ATC

Once the diagnosis of ATC has been established, optimal initial management requires close coordination and commu-

nication among multiple specialties. The timely, decisive input of all specialties is critical in defining the initial management plan.

Since the point of entry to the multidisciplinary team may be through an initial endocrine consultation, patients and family members may also expect the endocrinologist to remain involved in, and potentially also coordinate, the decision-making process and to serve as an advocate for the patient and their family. Early interactions with pain and palliative care specialists, social workers, clergy, and/or psychologists or psychiatrists are often also important components of a comprehensive approach.

Furthermore, it is important to also have readily available gastroenterological expertise (evaluation of nutritional status and potential need for enteral or parenteral nutritional support) and radiological expertise (timely interpretation of imaging studies needed to assess the extent and spread of the disease) in parallel.

Because formulation of the initial management plan requires rapid, complex, and integrated decision making, these patients should ideally be evaluated and cared for at medical centers that have in place highly functional multidisciplinary management teams. The rarity of the disease, coupled with the breadth of knowledge required to arrive at initial treatment recommendations, makes it quite challenging for even the most experienced thyroid cancer specialist to care for these patients outside of an established thyroid cancer disease management team.

On the other hand, should logistic or geographic issues preclude rapid access to a medical center with appropriate multidisciplinary management teams, the urgency of appropriate care for ATC requires that such care be rendered by the best available clinicians in local facilities.

■ RECOMMENDATION 12

A comprehensive multimodality management plan should be rapidly formulated and implemented by a multidisciplinary thyroid cancer management team.

Strength of Recommendation: Strong

Quality of Evidence: Low

Prognostic factors

ATC is an aggressive tumor with a poor prognosis (1,84,105–107); median survival is only about 5–6 months and 1-year survival is ~20% (1,106). Relevant prognostic features include socioeconomic status, tumor stage, increasing age, and sex (108). In a retrospective review of 121 patients with ATC, age <60 years, tumor size <7 cm, and less extensive disease at presentation were independent characteristics of decreased disease-related mortality (109). In a separate study of 47 patients with ATC, the presence of acute symptoms, tumor size >5 cm, distant metastases, and leukocytosis were each independent significant risk factors predicting a poor outcome and increased risk of death (61). Increased survival is associated with greater extent of surgery, younger age, smaller tumor size, higher dose radiotherapy, absence of distant metastases at presentation, coexistence of DTC, and management using multimodal therapy (1,84).

Kebebew *et al.* (110) utilized the SEER (Surveillance, Epidemiology, and End Results) database to analyze clinical characteristics of 171 men and 345 women with ATC. Thyroid

cancer-specific mortality rates were 68% at 6 months and 81% at 1 year. Similar to the studies noted above, poor prognostic characteristics included male sex, age >60 years, and the presence of extrathyroidal involvement. Women under age 60 years had a better prognosis when they had surgical excision and/or external beam radiotherapy. Tan *et al.* (101) also observed enhanced survival in women as compared to men, but this sex difference has not been consistently observed (14,15,58,107,108,111,112). Further studies assessing the ability of markers to predict mortality are needed.

With regard to risk factors, ATC frequently occurs in a setting of previous or concurrent benign or malignant thyroid disorders. Demeter *et al.* (113) studied 340 patients with thyroid cancer. Of the 17 (5%) with ATC, 13 (76%) had a history of a previous thyroid disorder, primarily benign goiter, or DTC. Clinical factors such as younger age, smaller tumor size, disease confined to the thyroid gland, absence of distant metastases, and complete resection of the primary tumor are associated with the subset of ATC patients with the best prognosis.

Akaishi *et al.* (114) reviewed 100 patient charts with ATC. Only six patients were noted to have a small ATC within a more DTC component. Total resection was achieved in 24 of 70 patients who were operated upon. External radiation was administered to 78 subjects; 15 patients were able to receive multiple treatment modalities (e.g., surgery, radiotherapy, and chemotherapy). Survival rates at 1 year were 72.7%, 24.8%, and 8.2% for patients with disease stage IVA, IVB, and IVC, respectively. Several characteristics, such as age \geq 70 years, extrathyroidal invasion, and distant metastases at presentation were associated with poorer outcomes. A complete resection, as compared to no resection for debulking, is associated with better overall survival.

■ RECOMMENDATION 13

ATC is an aggressive tumor with a poor prognosis and high mortality. Assessment of predictive factors such as age, sex, tumor size, histology, and clinical stage should be performed in all patients.

Strength of Recommendation: Strong
Quality of Evidence: Moderate

ESTABLISHING TREATMENT GOALS

Treatment and care goals

Advanced care planning and goals of care. Once the diagnosis of ATC has been verified, the attending physician should convene a multidisciplinary team discussion with subspecialists who may be involved in the patient's care (115–118), including palliative care expertise (119). This discussion should precede a discussion with the patient. The goal of this discussion is to reach consensus over the realistic treatment options that can be offered to the patient to improve continuity of care and reduce internal disagreement over goals of care. Overly optimistic messages to patients, as well as overly pessimistic messages, can dramatically affect advanced care planning discussions with patients (120–124), patient decision making, well-being, and beneficent care (125).

■ RECOMMENDATION 14

Physicians involved with the management decisions in the care of the patient should consult with multidisciplinary

specialists who may be involved in the care of the patient, either at the present time or in the future, before having "goals of care" discussions with patients.

Strength of Recommendation: Strong
Quality of Evidence: Low

Decision-making capacity and informed consent. Decision-making capacity means that patients have the ability to understand and appreciate the relevant information necessary to make an informed medical decision (126).^{*} There are many barriers to decision-making capacity, which include the physical or psycho-social consequences of having a serious illness, as well as factors such as language; literacy; numeracy; pain or delirium; mental health disorders, such as depression, anxiety, or serious addictions; and untreated mental illnesses, such as schizophrenia (130). Patients without adequate decision-making capacity cannot provide genuine consent to treatment. Assessing decision-making capacity supports both the principles of autonomy and beneficence because patients who are not able to make autonomous decisions require special protections through surrogate decision making according to patient preferences (if known) or in the patient's best interests (131,132). Autonomous decisions must also be voluntary, without coercion (133). The following questions can help to assess decision-making capacity. The first three questions assess understanding, and the last four questions assess appreciation and rationality (134).

- What do you understand to be the current situation?
- What are your treatment options?
- What will happen when you take this treatment? What makes you not want this treatment?
- Why do you want this treatment?
- What other choices do you have?
- Tell me about the decision. How did you arrive at your choice?
- What questions do you have? Is there anything that you are particularly worried about?

■ RECOMMENDATION 15

Patients must have decision-making capacity to consent to or make particular medical decisions. Concerns about diminished or impaired capacity may prompt a psychiatric consult or clinical ethics consult to assess barriers to capacity.

Strength of Recommendation: Strong
Quality of Evidence: Low

Surrogate decision making. The ethical principle of *autonomy/respect for persons* obligates health care providers

^{*}The Patient Self-Determination Act (127,128) requires hospitals, nursing homes, and other health care facilities to ask about Advance Directives or to record patient preferences regarding certain treatments should the patient lose decision-making capacity. Additionally, all states have specific health care laws that include proxy/surrogate decision making. See for example, New York State's *The Family Health Care Decisions Act* [N.Y. Pub. Health—Article 29-CC (2994-A-2994-U)], which reflects more flexibility in who can act as a surrogate. Other states, such as in Tennessee, Virginia, Georgia, Pennsylvania, Delaware, and Utah have specific laws regarding who may serve as surrogate decision makers (129). For information on a particular state's health laws, contact your state legislature or institutional health law office.

to seek out surrogate decision makers for patients who do not have decision-making capacity. Surrogate decision makers are required to make decisions according to the patient's preferences (if known) or in the patient's best interests if preferences are unknown. If the patient has not appointed a surrogate decision maker and/or has no Advance Directive, physicians should be aware of their state's laws surrounding proxy decision making. Local jurisdiction surrogacy laws may vary. In the United States, some states have family hierarchy laws, while some do not. If there are questions about who may serve as the patient's surrogate decision maker, treating physicians should consult with their hospital ethics committee or hospital attorney about appointing a proxy decision maker.

■ RECOMMENDATION 16

If patients require a surrogate (proxy) decision maker, the treating physician should ensure that one is appointed according to the patient's stated preferences if known (written or verbal) or in compliance with local jurisdiction laws surrounding surrogacy and guardianship in consultation with a hospital ethicist or attorney.

Strength of Recommendation: Strong
Quality of Evidence: Low

Truth-telling, patient autonomy, and beneficent care. *Beneficent care* refers to care in which clinical benefits are maximized, while potential clinical harms are minimized (135,136). What constitutes clinical harms in ATC management may be highly variable and can depend on a range of circumstances such as the patient's age, comorbid conditions, tumor status, overall health, and psychosocial support system. Thus, clinical management must be guided by patient preferences with respect to quality of life, which become known through an in-depth candid discussion with the patient, in which there is full disclosure of the diagnosis, realistic prognosis, and treatment options available for prolonging life (137,138). In this discussion, all relevant potential risks and benefits of available therapies must be disclosed (139). The concept of innovative therapy should be fully explained to the patient; *innovative therapy* refers to a treatment plan developed for a patient in the absence of a proven standard therapy, in which the goal is beneficent care for the patient and not the collection of data for generalizable knowledge (140,141). However, if the patient is being considered for or is enrolling in a clinical trial, this must be fully disclosed, and the informed consent procedures for the trial must be followed.

As appropriate, the patient should be provided, as one available option, palliative care and aggressive pain management, as well as the option to discuss his or her distressing diagnosis and end-of-life issues with psychosocial experts, including pastoral care (119,142,143). The early introduction of psychosocial support and pastoral care can help to reduce what is known as "existential suffering" in patients who may need to have closure about their life events or life relationships (144).

■ RECOMMENDATION 17

In consultation with a multidisciplinary team (see **Recommendation 14**), a candid meeting with the patient should be scheduled in which there is full disclosure of the potential risks and benefits of various treatment options, including

how such options will impact the patient's life. Treatment options discussed should include palliative care. Patient preferences should guide clinical management.

Strength of Recommendation: Strong
Quality of Evidence: Low

Advance directives, surrogate decision making, and code status. All ATC patients with decision-making capacity should be encouraged to draft an *advance directive*, which names a surrogate decision maker in the event the patient loses the ability to communicate wishes (145,146). Although advance directive forms in the United States vary from state to state, these documents can also specify patient preferences regarding intubation, nutrition supplementation and hydration, the placement of feeding tubes, intravenous ports, and tracheostomy, as well as code status, such as *do not resuscitate* (DNR). A newer term, *allow natural death* (AND), may be used as an alternative order (147) in limiting aggressive care and one which patients, families, and health care providers may better understand and appreciate. Advance directive documents can be highly problematic because they do not account for many of the nuances in intensive care unit care; additionally, DNR can have multiple meanings for practitioners, and reversible conditions, for example, may go untreated, which can hasten death (147–149). For these reasons, using the term AND is recommended over DNR when discussing end-of-life preferences with patients (147). Clinical ethicists recommend that naming a surrogate decision maker is the most important feature of advance directives (145,146). The surrogate should then be asked to make substituted decisions based on the patient's preferences. Naming a surrogate decision maker is particularly important for patients with no living family members. In states with family hierarchy laws, patients without a designated surrogate could have decisions being made by estranged spouses or other relatives (150).

Patients should be asked about code status preferences, nutrition, and hydration at an appropriate juncture, guided by a values history (151,152). Patients who have indicated they wish to be DNR or AND should be asked about suspension of such orders during surgery (153) or during other palliative procedures (154).

■ RECOMMENDATION 18

Patients should be encouraged to draft an advance directive in which they name a surrogate decision maker and list code status and other end-of-life preferences. Consider, in some cases, using "allow natural death" (AND) over "do not resuscitate" (DNR), which may be better understood by patients and families as an order that limits inappropriate aggressive care. Circumstances in which suspension of DNR or AND may occur must be discussed with the patient.

Strength of Recommendation: Strong
Quality of Evidence: Low

APPROACHES TO LOCOREGIONAL DISEASE

Roles of surgery

The initial approach to patients with stage IVA or IVB disease depends on whether the tumor is resectable (Fig. 2) or unresectable (Fig. 3) at the time of diagnosis.

Criteria for resectability. In patients with a preoperative diagnosis of ATC, the two criteria used to determine whether the tumor is resectable for curative intent are (i) distinguishing between locoregional disease and distant metastatic disease, and (ii) extent of local invasion and the structures involved. In patients with locoregional disease, the determination of whether the tumor is resectable should be based on what structures are involved, whether a satisfactory resection can be achieved (R0/R1), and whether resection of the involved structure results in significant morbidity or mortality. Gross tumor resection, not debulking, is the goal of surgery.

ATC can invade structures in the central and lateral neck and mediastinum by direct tumor invasion or by lymphatic invasion. Locoregional invasion into the internal jugular vein, carotid artery, nerves (e.g., recurrent laryngeal, vagus, spinal accessory, and phrenic), sternocleidomastoid muscle, esophagus, trachea, and/or superior vena cava is not uncommon and needs to be evaluated to determine resectability. Therefore, routine preoperative imaging in all patients should be performed to evaluate the extent of disease locally and to exclude the presence of distant metastasis. A high-resolution ultrasound of the neck should be obtained to evaluate the primary thyroid tumor and to assess for involvement of the central and lateral lymph node basins. Cross-sectional imaging of the neck and chest with MRI and/or CT scan is also imperative to determine the presence of regional disease and exclude distant metastasis. For better evaluation of the extent of disease, CT scan with intravenous contrast will be helpful. In patients with symptoms suggesting recurrent laryngeal nerve invasion, tracheal and/or esophageal invasion, a direct laryngoscopy, bronchoscopy, and esophagoscopy, respectively, should be performed. Patients with locoregional disease should be offered a resection if gross tumor resection can be achieved with minimal morbidity. This is because most

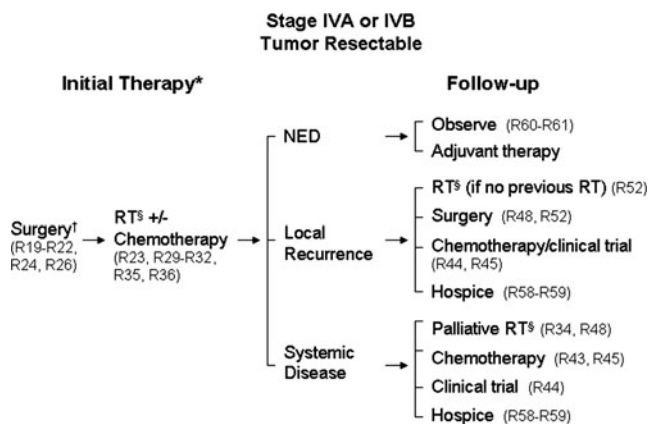


FIG. 2. Patients with anaplastic thyroid carcinoma, resectable disease, and no distant metastases should be considered for surgery and locoregional radiation therapy (with or without systemic therapy). Follow-up management options depend on whether the patient has no evidence of disease or local recurrence, or progresses to systemic disease. *Patient may decline surgery and/or RT ± chemotherapy (**Recommendation 34**) and prefer palliative/hospice care. [†]Neoadjuvant RT ± chemotherapy may precede surgery (**Recommendation 33**). [§]Intensity-modulated radiation therapy (IMRT) is preferred if possible. RT, radiation therapy; NED, no evidence of disease.

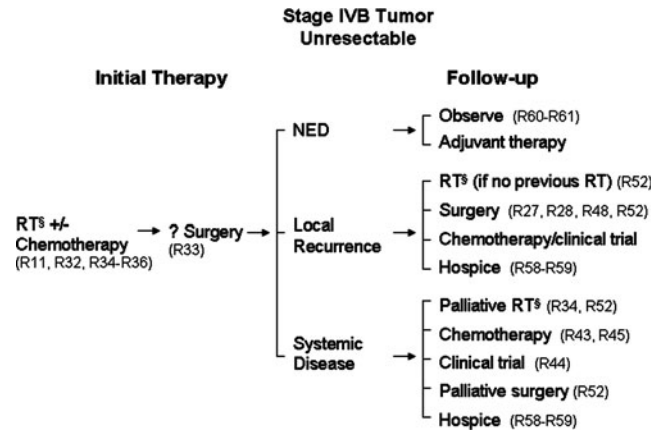


FIG. 3. Patients with anaplastic thyroid carcinoma who present with locoregionally confined but unresectable disease should consider radiotherapy with or without systemic therapy. Some patients may subsequently be deemed to have resectable tumor. Follow-up therapy options depend on patient responses to the initial therapy. [§]IMRT is preferred if possible.

studies suggest complete resection (R0/R1) is associated with prolonged disease-free survival and/or overall survival with or without combination chemotherapy and radiotherapy (2,58,101,112,155-162). There are insufficient data to determine if there is a difference in disease-free survival rates between patients who have grossly negative margins (R1 resection) versus microscopic negative margins (R0 resection). In patients with systemic disease, resection of locoregional disease for palliation may be considered if there is impending airway or esophageal obstruction.

RECOMMENDATION 19

Resectability of ATC should be determined by routine preoperative imaging studies (ultrasound, CT, MRI, and/or PET scan of the neck and chest). If locoregional disease is present and a grossly negative margin (R1 resection) can be achieved, surgical resection should be considered. In patients with systemic disease, resection of the primary tumor for palliation should be considered to avoid current or eventual airway or esophageal obstruction.

Strength of Recommendation: Strong
Quality of Evidence: Moderate

Optimal extent of surgery and control/survival. Approximately 10% of patients with ATC present with only an intrathyroidal tumor, whereas 40% have extrathyroidal invasion and/or lymph node metastasis, with the remainder of patients presenting with widely metastatic disease (58,163). Total or near-total thyroidectomy with therapeutic lymph node dissection of the central and lateral neck lymph node compartments should be considered in patients with resectable disease. The rationale for a total or near-total thyroidectomy is that approximately 20% of patients with ATC have coexisting DTC, and a complete resection (R0/R1) is associated with improved disease-free survival and overall survival with or without combination chemotherapy and radiotherapy (2,58,71,101,112,155-162,164). Although there are insufficient

data regarding the outcome from thyroid lobectomy in patients with localized and resectable ATC, it is reasonable to consider this procedure when there is concern for or documented injury to the ipsilateral recurrent laryngeal nerve, or removal of or no identification of the ipsilateral parathyroid glands. If there is extrathyroidal invasion, an en bloc resection (but not total laryngectomy) with the goal of achieving gross negative margins should be considered. The aggressiveness of the operative resection should be considered in the context of morbidities that may occur from resecting adjacent involved structures. If complete resection (R0/R1) can technically be achieved with minimal morbidity, it should be performed and may be associated with improved survival (114,164). Total laryngectomy is not likely to be beneficial given the morbidity associated with this procedure and the high likelihood of recurrent and or persistent disease. Similarly, incomplete resection or tumor debulking (R2) should also not be performed because it is unlikely to be beneficial for local control and/or survival.

■ RECOMMENDATION 20

A total lobectomy or total or near-total thyroidectomy with a therapeutic lymph node dissection should be performed in patients with intrathyroidal ATC.

Strength of Recommendation: Strong
Quality of Evidence: Moderate

■ RECOMMENDATION 21

In patients with extrathyroidal invasion, an en bloc resection should be considered if grossly negative margins (R1 resection) can be achieved.

Strength of Recommendation: Strong
Quality of Evidence: Moderate

Need for surgery after up-front radiotherapy and/or chemotherapy in initially unresectable ATC. Some patients with ATC who receive initial radiotherapy with or without chemotherapy will have a PR—or rarely a CR—to treatment (112,155,156,165,166). In such cases, the tumor may become resectable even if initially unresectable. Although external beam radiation may result in significant fibrosis and scarring making surgical resection difficult, patients who have a durable response and who have residual disease may be considered operative candidates if there is no other disease outside the neck. There are, however, limited data in the literature to determine if such an aggressive approach results in improved disease-free survival and overall survival. One of the main rationales for such an approach is that the relapse rate after PR or CR to radiotherapy is high, and operative resection may reduce the risk of local relapse (112).

Incidental ATC: surgical management. At the time of diagnosis, ATC is confined to the thyroid (T4a) in 2%–15% of patients (58,110,157,163,167,168). Even more uncommonly (2%–6% of cases), the ATC is identified as a small, incidental finding after surgical resection of a predominantly non-anaplastic tumor (155,169,170). Although there are unfortunately no meaningful data to define the best approach in this context, completely resected intrathyroidal ATC is clearly associated with a better prognosis (109,110). Expert opinion therefore differs with regard to whether patients with small, incidentally detected ATC contained within more differenti-

ated neoplasms might benefit from adjuvant therapy beyond initial surgical resection. Likewise, the role for completion thyroidectomy (if only an initial lobectomy was performed) is based more upon the characteristics of the non-anaplastic malignancy than on the incidental finding of anaplastic microcarcinoma, including the findings of preoperative imaging studies evaluating the contralateral lobe for the initial lobectomy. There are insufficient data to demonstrate a difference in disease-free survival or cause-specific mortality based on the extent of thyroidectomy for an incidental (microscopic) focus of ATC.

There are recently emerged data indicating apparent clinical benefit and possible improvement in survival from the application of adjuvant combined modality chemotherapy and radiation therapy in locoregionally confined ATC, after complete/near complete resections or in patients with unresected disease, as discussed in the later sections on radiotherapy. The question remains open, therefore, as to whether intrathyroidal incidentally detected ATC is best treated with surgery alone, surgery followed by radiotherapy, or surgery followed by chemotherapy plus radiation therapy.

■ RECOMMENDATION 22

A total lobectomy or total or near-total thyroidectomy should be performed in most patients with an incidental area of ATC within a DTC. This is based primarily on treatment recommendations related to the non-anaplastic component of the malignancy.

Strength of Recommendation: Strong
Quality of Evidence: Low

■ RECOMMENDATION 23

The data are inadequate to definitively recommend either for or against local or systemic adjuvant therapy for small, intrathyroidal ATCs. A majority of the authors would favor cautious observation with frequent anatomic imaging studies for at least the first year of follow-up, while a minority would recommend adjuvant therapy.

Strength of Recommendation: Weak
Quality of Evidence: Low

Surgical risk to recurrent laryngeal nerve. If a patient presents with ipsilateral recurrent laryngeal nerve palsy, one needs to be extremely careful in the operating room to avoid injury to the opposite recurrent laryngeal nerve. Any injury to the opposite side may lead to airway-related issues and may precipitate airway distress requiring reintubation or a tracheostomy. In most cases, the need for elective tracheostomy can be determined by evaluating the integrity of the recurrent laryngeal nerve using a nerve stimulator at the time of the operation. However, such a problem intraoperatively or postoperatively is rare. If there is any concern regarding the recurrent laryngeal nerve, one may consider leaving some thyroid tissue on the nerve on the other side. Occasionally, if the tumor involves a single lobe and there is concern about resecting the normal contralateral lobe, one may consider leaving normal thyroid tissue behind as these patients do not respond to radioactive iodine (RAI). The need for tracheostomy on an emergent basis postoperatively is quite rare (58,110,171,172). However, during the course of postoperative follow-up, the patient's tumor may grow, causing involvement of the opposite recurrent laryngeal nerve, which

generally happens over a period of time, and the patient will present with progressive dyspnea or stridor.

■ RECOMMENDATION 24

Every attempt should be made to identify the contralateral recurrent laryngeal nerve, especially if the ipsilateral nerve is paralyzed, to protect the nerve from injury, which may lead to bilateral vocal cord paralysis and requirement for tracheostomy. A nerve monitor may be quite helpful to confirm nerve function.

Strength of Recommendation: Strong
Quality of Evidence: Low

Airway management and indications for tracheostomy. Tracheostomy in patients with ATC is performed to support an airway in extreme circumstances of life-threatening asphyxia. Most patients who require a tracheostomy in ATC have an extremely guarded prognosis and progression of disease. Tracheostomy is best avoided as long as possible. However, if the patient is in severe airway distress, he or she should be brought to the operating room since tracheostomy is best performed under anesthesia with preoperative intubation. Additionally, some patients will require an isthmusectomy or debulking of the pretracheal tumor to obtain adequate access for a tracheostomy. An attempt to perform the tracheostomy either on the ward or in the emergency room under local anesthesia should be avoided (172,173).

■ RECOMMENDATION 25

Patients with ATC may require tracheostomy to avoid asphyxia. It should be done in an operating room setting, unless acute airway distress demands immediate action.

Strength of Recommendation: Strong
Quality of Evidence: Low

Securing the airway after surgery. After the surgical procedure, the patient should remain intubated for a short period of time and extubated either in the operating room itself or in the recovery room with close observation. If the airway was secure preoperatively, most patients will not have postoperative airway-related issues. However, if there is an airway-related issue the patient should have direct laryngoscopy evaluation and be reintubated, and extubated under optimal circumstances with close observation. If there is any continued major concern about stridor or shortness of breath, the patient will require reevaluation and possible semi-elective tracheostomy, which should be performed in the operating room (172,173).

■ RECOMMENDATION 26

The patient's airway should be closely monitored in the recovery room during the postoperative period and throughout radiation therapy. Elective tracheostomy is best avoided unless there are acute airway issues.

Strength of Recommendation: Strong
Quality of Evidence: Low

Benefits of tracheostomy. This continues to be a subject of considerable controversy in the management of patients with ATC. Tracheostomy does prolong life, as it overcomes acute airway distress and impending mortality. However, the pa-

tients with ATC who require tracheostomy have advanced local disease, and the chances of long-term survival are quite small. Under these circumstances, the tracheostomy may prolong some suffering. Tracheostomy does lead to secretions, need for frequent suctioning, and overall discomfort that the patient may experience. However, it does overcome acute airway distress with some prolongation of life. Whether that is meaningful or not remains controversial (58,110,171–173).

■ RECOMMENDATION 27

Tracheostomy may be temporarily beneficial in patients with impending airway loss.

Strength of Recommendation: Strong
Quality of Evidence: Low

Surgical airway and unresectable disease. Most patients with ATC will not require surgical airway intervention unless the patient has severe stridor or acute airway distress. The presence of a tracheostomy tube and secretions will lead to considerable discomfort on the part of the patient, and there is generally no need for creation of a surgical airway, even in patients with unresectable ATC.

■ RECOMMENDATION 28

Tracheostomy or stent placement is best avoided unless there is impending airway compromise.

Strength of Recommendation: Strong
Quality of Evidence: Low

Radiotherapy and systemic chemotherapy in locoregional ATC

The application of radiotherapy and/or systemic chemotherapy in locoregionally confined (IVA/B) ATC should be tailored to the capabilities and directives of the patient in coordination with the treatment team in accord with the intended goals. Critical in defining approaches to be used are (i) the wishes or directives of the patient, (ii) the fitness of the patient to undergo candidate therapeutic approaches, (iii) the availability of treatment approaches at intended treatment site(s), and (iv) the intended goals of therapy merged with discussions of the patient's aversion to risks of candidate therapeutic approaches.

In general, initial treatment goals first need to be established as either palliative or curative in intention, realizing that interval developments in terms of tumor response and progression and also in terms of interval adverse events will necessarily shape therapy once underway. Typically, the mainstays of therapy in addition to surgery can involve locoregional approaches, most commonly radiotherapy (but sometimes also interventional radiological approaches), and systemic approaches, most commonly cytotoxic chemotherapy (but sometimes also novel targeted therapeutics).

Radiotherapy after complete or near-complete (R0 or R1) resection. The best results in terms of both local control and survival from numerous studies appear to result from surgical resection followed by radiation therapy, usually in combination with chemotherapy. However, there is always an element of case selection bias because, invariably, patients with better performance status, younger age, and less extensive disease receive more aggressive combination therapy than older patients with extensive unresectable or metastatic

disease. The SEER data of 516 patients revealed in a multivariate analysis that, along with age, only the combined uses of surgical resection and external beam radiotherapy were identified as independent predictors of survival (110). Given the large numbers and that this was a population-based study, these data provide the strongest evidence available that the combination of surgery and radiation is important.

Similarly, in another smaller population-based study from British Columbia analyzing 75 patients, survival was better in patients who had more extensive surgery and had high-dose radiation with or without chemotherapy (158). In contrast, a large single-institution review of 134 patients from the Mayo Clinic found that the extent of surgery did not correlate with survival. In the Mayo Clinic series, postoperative radiation was associated with an improvement in median survival from 3 to 5 months, but this was not statistically significant ($p=0.08$) (58). In general, however, most single-institution studies report improved results due to the combination of surgery and radiation with or without chemotherapy (2,15,62,104,114,155–157,159–162,169,174–178).

In the majority of series, radiation is given after surgery; however, in a few, preoperative radiation has been given, and in some series radiation is performed pre- and postoperatively. Brignardello *et al.* (159) reported best results in their series after maximum surgical debulking and postoperative chemoradiation therapy. They reported that radiation therapy was of unlikely benefit in terms of permitting subsequent surgical resection in patients who had initially unresectable disease because in only one out of five cases was resection subsequently possible. In contrast, Besic *et al.* (169) concluded that preoperative therapy was preferable to postoperative therapy. Ninety-nine patients were considered initially unresectable and treated with up-front chemotherapy and/or radiotherapy followed by surgery if possible, although it is not clear how many had subsequent surgery. Busnardo *et al.* (176) reported that preoperative chemoradiation improved operability. Tennvall *et al.* (166) used a sandwich approach with preoperative chemoradiation followed by surgery then further chemoradiation, but more recently have given preoperative chemoradiation then surgery, then more chemotherapy without radiation. In this latest series, 17 out of 23 patients were able to undergo some form of surgery, two with gross residual disease. Despite this approach, the median survival was only 2 months.

In patients with initially resectable disease, there does not appear to be any substantive evidence that preoperative is preferable to postoperative radiation therapy. Surgical resection may therefore reasonably be performed first, with postoperative chemoradiation therapy given subsequently depending upon outcome. However, in patients with initially unresectable disease, chemoradiation may rarely enable subsequent resection and should be considered in patients with good performance status and without metastatic disease. However, the potential benefit in a few must be weighed against the risk of toxicity in a population of patients, the majority of whom still have a poor survival.

■ RECOMMENDATION 29

Following an R0 or R1 resection (excluding an incidental intrathyroidal microscopic lesion; see **Recommendation 23**),

patients with good performance status with no evidence of metastatic disease who wish an aggressive approach should be offered definitive radiation therapy (with or without concurrent chemotherapy, see **Recommendation 36**).

Strength of Recommendation: Strong

Quality of Evidence: Moderate

Timing and sequencing of perioperative radiation and/or systemic chemotherapy. There are no definitive data that indicate when radiation and systemic therapy should start or how they should be sequenced. Some physicians may prefer sequential therapy. However, given that ATC grows very rapidly, it is probably prudent to start as soon as feasible. Radiotherapy can generally begin after preliminary postoperative healing has transpired and when the patient has recovered sufficiently to lie supine and enable immobilization. In particular, radiation treatment planning should begin expeditiously when postoperative swelling has gone down, ~2–3 weeks after surgery. Depending on the time required for treatment planning with three-dimensional (3D) conformal radiation or intensity-modulated radiotherapy (IMRT), treatment may start with a parallel pair beam arrangement until the final treatment plan is available, which should be ≤ 1 week. In terms of time of initiation of systemic therapy if elected, this too should begin expeditiously. However, systemic chemotherapy can often be initiated more quickly after surgery than can radiotherapy because less postoperative healing is required for its safe administration.

■ RECOMMENDATION 30

Treatment should be planned and radiation started as soon as the patient is sufficiently recovered from neck surgery, usually within 2 to 3 weeks after surgery.

Strength of Recommendation: Strong

Quality of Evidence: Low

■ RECOMMENDATION 31

Systemic chemotherapy can begin as soon as the patient is sufficiently recovered from surgery, potentially even within 1 week of surgery, depending upon postoperative course and treatment goals.

Strength of Recommendation: Strong

Quality of Evidence: Low

Locoregional radiotherapy and/or systemic therapy in patients with unresected disease. Even in patients with unresected disease (after an R2 resection or if surgery is not performed), radiation therapy can achieve long-term local control. Several series show better response rates with higher dose radiation. However, these data must be interpreted with caution since all such studies are retrospective, and patients with less extensive disease and better performance status are more likely to be given high-dose radiation therapy. Levendag *et al.* (167) reported that patients who received <30 Gy had a median survival of 1 month compared with 3.3 months if >30 Gy was given. Pierie *et al.* (155) also reported that patients who had ≥ 45 Gy had a better survival. Swaak-Kragten *et al.* (156) reported that the median survival was 5.4 months if patients were given >40 Gy but only 1.7 months if <40 Gy was given. Wang *et al.* (168) reported the median survivals were 3 months if <40 Gy and 11 if >40 Gy was prescribed. In a recent report on the experience with radiation

and weekly doxorubicin a median survival of 6 months was reported (179). When the radiation dose was ≥ 50 Gy, median survival was 8.5 months, and if >60 Gy was given, median survival increased to 14.1 months. Levendag *et al.* (167) reported that median survival in patients with metastatic disease was improved if local control was achieved (8 vs. 2 months). This must be tempered by the overall poor survival of patients with metastatic disease. These studies collectively suggest that high-dose radiation therapy is seemingly of value. How to select patients is uncertain, but patients with good performance status and no metastases should probably be offered high-dose radiation therapy. There is, however, also the suggestion that patients with limited metastatic disease may benefit from an aggressive approach to the neck to ensure long-term local control.

■ RECOMMENDATION 32

Patients who have undergone R2 resection or have unresected disease with good performance status and who wish an aggressive approach should be offered definitive radiation (with or without concurrent chemotherapy; see **Recommendation 36**).

Strength of Recommendation: Strong
Quality of Evidence: Moderate

■ RECOMMENDATION 33

Surgical resection may be reconsidered in patients when radiation (with or without chemotherapy) renders the tumor potentially resectable.

Strength of Recommendation: Strong
Quality of Evidence: Low

For patients with poor performance status who decline or who would not tolerate high-dose radiation, low-dose radiation may be of palliative benefit in controlling pain and possibly obstructive symptoms, but there are few data to support this. Junor *et al.* (112) reported a 40% CR rate from radiotherapy and a 42% PR rate for an overall response rate of 82% and a trend to increased survival with higher doses. Higher doses of radiation, however, did not improve response rate (doses of <20 Gy were excluded). Thus, there is probably a reasonable chance of response to less than radical doses of radiotherapy or to palliative radiation with modest doses. Lessened toxicity in response to a palliative radiotherapy program could therefore prompt consideration of such an approach in symptomatic patients not considered appropriate for high-dose radiation either because of performance status, widespread metastatic disease, or patient wishes.

■ RECOMMENDATION 34

Patients with local symptoms and poor performance status should be offered palliative radiotherapy.

Strength of Recommendation: Strong
Quality of Evidence: Low

Radiation dose, field, and techniques (conventional, altered fractionation, IMRT). The clinical target required to optimally manage irradiation with acceptable toxicity in the setting of either unresected or postoperative ATC has historically been difficult, often requiring a degree of compromise which can lead to undesirable dose reductions and/or in-

creased treatment morbidity. A variety of conventional two-dimensional (2D) and 3D planning techniques have been used over the years, but with IMRT it is possible to generate concave dose distributions and dose gradients with narrow margins so that complex volumes can be treated and adjacent normal structures such as spinal cord and salivary glands can be spared. There is strong evidence of the benefit of IMRT in improving outcome and reducing toxicity in other head and neck cancers (180,181).

In a comparison of conventional radiation, 3D conformal radiation therapy (3DCRT) and IMRT plans to the thyroid bed, and to the thyroid bed and locoregional lymph nodes, Nutting *et al.* (182) reported that 3DCRT reduced normal tissue irradiation compared with conventional techniques but did not improve tumor coverage or reduce dose to the spinal cord. In contrast, IMRT improved the tumor coverage and reduced the spinal cord dose (182). In a clinical comparison of conventional radiation and IMRT, Schwartz *et al.* (183) reported less late morbidity in 56 patients treated with IMRT compared with 76 treated with conventional radiation, but the difference was not statistically different. This study was in patients with DTC, not ATC. In a study of patients with ATC, with smaller numbers and shorter follow-up, the same group was unable to show a similar improvement in late morbidity (177). Cancer Care Ontario Program in Evidenced-Based Care has recently reviewed the evidence in support of IMRT for a variety of tumors (184). Although there was insufficient evidence in a systematic review to propose evidence-based recommendations for thyroid cancer, based on the data presented above the Ontario group concluded that there are compelling reasons why IMRT should be offered to patients with thyroid cancer as an alternative to conventional treatment planning. Because of the improved dose distribution and the ability to reduce toxicity, where available, patients should be irradiated with IMRT (177).

■ RECOMMENDATION 35

Patients who are to receive radiation for unresectable thyroid cancer or in the postoperative setting should, where available, be treated with IMRT; however, treatment should not be delayed because of lack of availability of IMRT.

Strength of Recommendation: Strong
Quality of Evidence: Low

Role of systemic therapy combined with radiation. In the past when chemoradiation has been given for thyroid cancer, radiation has been most often combined with doxorubicin. Tennvall *et al.* (166), using hyperfractionated radiation and doxorubicin with surgery when feasible, reported 9% 2-year overall survival; however, Pierie *et al.* (155) reported no improvement in disease-specific survival with the addition of chemosensitization (usually doxorubicin). Although the Mayo Clinic reported no improvement in median survival in patients receiving chemotherapy (generally also doxorubicin) and radiation, a greater proportion of patients survived >1 year (23% vs. $<10\%$), suggesting perhaps that systemic chemotherapy might have potential to treat micrometastatic disease and affect long-term survival (58). However, the addition of chemotherapy to radiation therapy also has potential to increase morbidity and potentially mortality (see also **Recommendation 41**).

Several more recent reports support the hypothesis that the addition of both radiosensitizing and adjuvant chemotherapy to surgery and radiotherapy may improve ATC outcomes. Among 30 patients treated with surgery, radiation therapy, and doxorubicin administered concurrently with radiation therapy and continued thereafter, Swaak-Kragten *et al.* (156) reported better 1-year survival (23% vs. 9%). Other agents such as cisplatin, which is a better established clinical head and neck radiosensitizing agent, have also been used, often in combination with doxorubicin, but no study has prospectively compared radiation alone to radiation and cisplatin. Haigh *et al.* (157) reported 75% 2-year survival in eight patients undergoing complete surgical resection and adjuvant radiation therapy and chemotherapy using a variety of different agents. Tan *et al.* (101) reported 5-year survival in three of five patients who underwent complete resection, four receiving postoperative radiation therapy and three receiving post-radiation doxorubicin chemotherapy.

There is increasing evidence that taxanes, which are also radiosensitizing agents, may be more effective chemotherapeutic agents than those traditionally used in ATC. In particular, Ain *et al.* (185) reported that single agent paclitaxel had a 53% transient response rate in 19 patients with advanced disease. Higashiyama *et al.* (104) reported a 33% response rate (including one CR) to paclitaxel when given preoperatively and a 44% 1-year survival in nine patients with stage IVB ATC treated with induction paclitaxel in comparison with 5.9% in a historical control group. Bhatia *et al.* (177) have reported as part of a larger cohort of 53 patients, six treated with continuous-infusion paclitaxel and twice-daily radiation in three separate week-long cycles. Of the 53 there were five long-term survivors, one treated with radiation and paclitaxel and the other four with cisplatin or carboplatin.

The taxane docetaxel has also been reported to produce encouraging results in ATC, especially when combined with radiation therapy. Troch *et al.* (186) reported four CRs and two PRs among six patients treated with combined docetaxel and IMRT, with five of six patients surviving >21 months. Similarly, among 10 consecutively treated ATC patients with locoregional disease, Foote *et al.* (187) reported that five patients were alive and cancer-free having been followed >32 months with a median overall Kaplan–Meier survival of 60 months (overall survival at 1 and 2 years was 70% and 60%, respectively) in response to IMRT combined with adjuvant and radiosensitizing chemotherapy. However, Kawada *et al.* (188)

reported a somewhat discouraging response rate of only 14% in response to docetaxel monotherapy in advanced ATC.

Compared with conventional radiotherapy, hyperfractionation may also increase radiation response rate at the cost of increased toxicity with the advantage of shorter overall treatment time, which can reduce the risk of tumor repopulation. This latter effect may be important in rapidly growing tumors such as ATC and has been used in combination with chemotherapy in several studies. Wang *et al.* (168) found in a study of radiation alone that hyperfractionated radiotherapy resulted in improved median survival (13.6 months) compared with conventional fractionation (10.3 months), although the difference was not significant. In contrast, Dandekar *et al.* (189) reported that with a hyperfractionated accelerated protocol with larger fraction sizes than usually given, there was no survival advantage but significant toxicity; altered fractionation was abandoned. There has been no comparison of altered fractionation alone compared with chemoradiation; therefore, either may be considered.

The toxicities associated with high-dose radiotherapy concurrent with chemotherapy are seen both in the acute and late setting. During chemotherapy and radiotherapy, patients' major complaints are dysphagia and odonophagia. Severe mucous production giving rise to a "choking" sensation and desquamation of the skin are also common side effects. The difficulty in swallowing can result in the placement of a percutaneous gastrostomy (PEG) tube. At this time, the treating physician should continue to counsel patients to swallow because the discontinuation of swallowing can result in PEG tube dependence. This is the major late complication associated with high-dose radiotherapy, and hence every effort to counsel patients to continue swallowing during radiotherapy is warranted. Examples of adjuvant or radiosensitizing chemotherapy regimens are listed in Table 5.

■ RECOMMENDATION 36

The use of cytotoxic chemotherapy involving some combination of taxane (paclitaxel or docetaxel), and/or anthracyclines (doxorubicin) and/or platin (cisplatin or carboplatin) therapy should be considered in combination with radiation therapy or altered fractionated radiotherapy in good performance status patients with nonmetastatic ATC who desire aggressive therapy.

Strength of Recommendation: Strong

Quality of Evidence: Moderate

TABLE 5. EXAMPLES OF ADJUVANT/RADIOSENSITIZING CHEMOTHERAPY REGIMENS IN ANAPLASTIC THYROID CARCINOMA

Regimen	Agents/dosages	Frequency
Paclitaxel/carboplatin	Paclitaxel 50 mg/m ² , carboplatin AUC ^a 2 mg/m ² IV	Weekly
Docetaxel/doxorubicin	Docetaxel 60 mg/m ² IV, doxorubicin 60 mg/m ² IV (w/ pegfilgrastim) or Docetaxel 20 mg/m ² IV, doxorubicin 20 mg/m ²	Every 3–4 weeks Weekly
Paclitaxel	Paclitaxel 30–60 mg/m ² IV	Weekly
Cisplatin	Cisplatin 25 mg/m ² IV	Weekly
Doxorubicin	Doxorubicin 60 mg/m ² IV	Every 3 weeks
Doxorubicin	Doxorubicin 20 mg/m ² IV	Weekly

^aCarboplatin AUC, carboplatin dosed using the Calvert formula with the Cockcroft & Gault equation, actual body weight, and using a minimum serum creatinine value of 0.7 mg/dL.

IV, intravenously.

Supportive care during active therapy

ATC itself poses imminent risk to patients both in terms of the threat to airway and esophagus due to local disease in the neck and potentially also consequent risk of metastatic disease. Moreover, during active treatment some existing patient risks are increased, while other new risks arise. The patient, family, and involved health care providers must be fully informed about these risks, with risk mitigation plans articulated.

It is critical that all involved be aware of the potential risks so as to identify and act on any emerging problems as they arise and without delay. Patients should be educated to be proactive in bringing emerging issues to the attention of their caregivers, and caregivers should be educated as to how to respond in the best interests of the patient given the unusual context of ATC under active therapy.

Airway management. Patients with ATC undergoing radiation therapy require close monitoring. The airway may become narrowed from the effect of ATC, vocal cord paralysis, or endolaryngeal edema due to radiation therapy.

■ **RECOMMENDATION 37**

In the absence of impending airway compromise, minor airway-related issues can be overcome with humidity, rest, and occasional use of short-term corticosteroids.

Strength of Recommendation: Strong
Quality of Evidence: Low

Maintenance of nutrition (PEG/feeding tube). Most patients with ATC, providing their nutritional status is good, can tolerate adequate oral nutrition and do not require enteral feeding. However, patients with esophageal obstruction who cannot tolerate adequate oral nutrition may benefit from enteral nutrition. Enteral nutrition may also be considered for patients prior to chemoradiation, depending on the protocol used, the degree of expected pharyngitis and esophagitis, and their nutritional status (179). Depending on the local expertise, gastrostomy for enteral feeding may be placed by one of the following specialists: gastroenterologist, interventional radiologist, or surgeon.

Placement of a PEG tube in a patient with ATC may be a challenge if there is considerable narrowing of the esophagus due to tumor invasion or obstruction, and the gastroscopically placed tube may be difficult to pass through. Radiologically directed placement of the tube may be undertaken. When irritation by the gastroscopically placed tube may lead to airway compromise, PEG tube placement with controlled intubation in the operating room or radiologically directed placement of the tube may be necessary.

■ **RECOMMENDATION 38**

If the patient with ATC has difficulty swallowing and treatment with surgery, radiation, or chemoradiation therapy is planned, gastrostomy for enteral nutrition should be considered.

Strength of Recommendation: Strong
Quality of Evidence: Low

■ **RECOMMENDATION 39**

A PEG tube may be difficult to place if the patient has involvement or obstruction of the esophagus. A percutaneous radiologically directed gastrostomy may be indicated in these patients.

Strength of Recommendation: Strong
Quality of Evidence: Low

Parenteral nutrition in perioperative management. Total parenteral nutrition (TPN) is rarely necessary or indicated in patients with ATC. The majority of patients will obtain adequate nutrition through the placement of a percutaneous gastrostomy tube. The practical need for TPN in patients with ATC is rare and should be considered only in extenuating circumstances. For instance, if the patient has responded to chemoradiation but the patient's nutritional status is deteriorating and either a gastrostomy tube cannot be inserted or enteral feeding is not tolerated, TPN may allow time to recover from the side effects of treatment.

■ **RECOMMENDATION 40**

Total parenteral nutrition is rarely necessary in patients with ATC.

Strength of Recommendation: Strong
Quality of Evidence: Low

Growth factor support during chemoradiation therapy. Adding chemotherapy to radiation therapy, with the aims of improving disease control in irradiated areas and, in parallel, preemptively treating microscopic metastatic disease, has the potential to increase toxicity. Among the most serious potential toxicities from chemotherapy is that of infection complicating chemotherapy-induced neutropenia; this risk is heightened by the concomitant use of chemotherapy and radiation. Further, mucositis or esophagitis is commonly induced by intensive radiotherapy, resulting in disruption of some of the usual mucosal defenses against infection. Collectively, these factors result in an inordinate risk of serious infection when combining chemotherapy with radiotherapy in ATC. Such risks can be lessened in several ways. First, any planned chemotherapy should take into account these risks, to use either a weekly administration strategy (so as to allow hiatus from therapy in the event of neutropenia) or alternatively use preemptive granulocyte colony-stimulating growth factor/pegfilgrastim support so as to minimize treatment-related neutropenia. Second, patients must additionally be made aware of the risks and cautioned to present immediately to medical attention upon attaining a fever of $>101^{\circ}\text{F}$ (38.3°C) so as to allow rapid palliation of neutropenic fever by prompt institution of intravenous antibiotics.

■ **RECOMMENDATION 41**

The use of preemptive granulocyte colony-stimulating growth factor/pegfilgrastim or weekly chemotherapy dosing regimens should be strongly considered when combining chemotherapy and radiotherapy in ATC so as to minimize the risks of treatment-related neutropenia and neutropenic infections.

Strength of Recommendation: Strong
Quality of Evidence: Low

APPROACHES TO ADVANCED METASTATIC DISEASE (STAGE IVC)

Figure 4 illustrates the approach to patients with metastatic disease. Establishing the overall goal, ranging from aggressive therapy to supportive care, allows the patient care team to initiate and monitor subsequent therapy in a manner understandable to the patient and family members.

Defining therapeutic goals, expected or possible adverse events, appropriate expectations, and limits of care

Patients with metastatic ATC almost uniformly have short survival and no prospects for curative outcome. Moreover, the use of aggressive approaches in metastatic ATC has never been definitively shown to improve survival. These factors combine to make it imperative that the formulation of treatment plans in patients with metastatic ATC be undertaken only after careful discussions of the expected risks and benefits of available palliative active therapies versus those expected from hospice/best supportive care approaches. In this setting, resuscitation/code status should be established and Advance Directives procured early on. Please refer to the section **Establishing Treatment Goals** for additional discussion of these important topics.

Timing of systemic therapies

The administration of cytotoxic and/or targeted systemic therapies in metastatic ATC has never been definitively shown to have curative potential or to improve survival or quality of life. In advanced disease, decisions related to the timing of administration of systemic therapies relative to palliative focal therapies depend greatly on the specifics of the case. In general, if a patient has symptomatic or imminently threatening focal disease that can be treated with focal measures (e.g., radiation therapy) then systemic therapy should follow, and not precede, focal therapy. If diffuse disease progression instead poses the primary threat, systemic therapy should be considered as an alternative to palliative locoregional therapies that otherwise neglect the bulk of disease and imminent global threat to the patient. Additionally, as the rate of disease progression in ATC tends to be very fast, delaying consideration

of systemic therapy in ATC if desired by the patient is generally unwise because such a delay may be met with disease progression sufficient to make the patient less tolerant or unsuitable for later systemic therapy. Because inclusion criteria for clinical trials tend to be rigid, clinical trials—if suitable and desired by the patient—should be considered earlier on; however, initiation of systemic therapy if desired and suitable for a particular patient should be expeditious.

■ RECOMMENDATION 42

Palliation of symptomatic and/or imminently threatening lesions should be given high priority in comparison to treatment with systemic therapy unless the primary threat to the patient is diffuse disease progression.

Strength of Recommendation: Strong

Quality of Evidence: Low

Approaches to systemic disease (cytotoxic)

There are no randomized trial data to conclusively demonstrate that survival is prolonged or quality of life improved in ATC patients in response to treatment with systemic therapy. Nonetheless, tumor regression can be induced in response to systemic therapies in some ATC patients, with anecdotal and nonrandomized study evidence supporting its use in selected patients as summarized in the following subsections. Risks and potential benefits must be carefully considered in the context of each patient in individualizing care in accord with patient directives.

Taxanes. A multicenter clinical trial conducted by Ain *et al.* (185) demonstrated that the taxane paclitaxel administered weekly or every 3 weeks resulted in transient disease regression in 53% of 19 evaluable patients, with anecdotal evidence suggestive that weekly therapy may be superior to 96-hour infusional therapy every 3 weeks. However, reported dosages of paclitaxel (225 mg/m² intravenously [IV] weekly) were incorrect (personal communication from author Dr. Kenneth Ain) since paclitaxel dosages should instead be 60–90 mg/m² IV weekly to assure safety. Moreover, criteria for response in this trial required maintenance of response for only 2 weeks, rather than the typical 4 weeks utilized in the National Cancer Institute RECIST criteria, making study results difficult to interpret in the context of studies using RECIST response criteria. Although survival data are reported, the trial was not randomized or case-controlled, so the full impact of paclitaxel therapy on survival remains difficult to accurately assess.

Anecdotal experience, however, suggests that single agent paclitaxel can have disease-modifying effects in some patients [as indicated by Ain *et al.* (185)] and may impact survival in a subset of treated patients. Further, a recent report indicated also that the taxane docetaxel at a dosage of 60 mg/m² IV administered as a single agent every 3 weeks can occasionally even produce CRs—but more commonly stabilize disease for a time (188). In this study, one of seven patients had CR lasting 50 weeks, but median time to progression was only 6 weeks.

Anthracyclines and platins. Doxorubicin, 20 mg/m² IV weekly or 60–75 mg/m² IV every 3 weeks has also been used in advanced ATC, and it is the only cytotoxic chemotherapy specifically approved by the U.S. Food and Drug Administration for use in ATC. Published studies of the application of

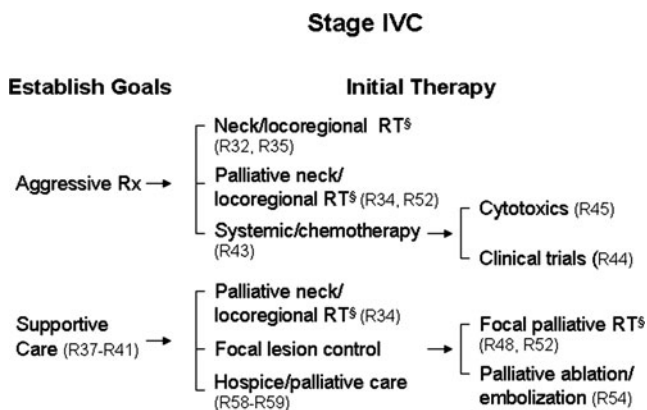


FIG. 4. After initial evaluation and staging, patients who present with distant metastases should decide whether to pursue aggressive therapy or supportive care, which may include palliative procedures. §IMRT is preferred if possible.

doxorubicin in ATC, however, generally discuss its use in combination with surgery and radiotherapy, making assessment of response rates and impact on survival uncertain in advanced disease (166,190). However, in a trial conducted by the Eastern Cooperative Oncology Group (191) from 1976 to 1982, 84 patients with advanced progressive thyroid cancer of all histotypes (not specifically ATC) were randomized to receive doxorubicin alone (60 mg/m² IV every 3 weeks) or doxorubicin plus cisplatin (60 mg/m² IV doxorubicin, 40 mg/m² cisplatin IV every 3 weeks). In 39 patients with ATC on this study, doxorubicin alone produced no CRs and one PR in 21 treated ATC patients, while doxorubicin plus cisplatin yielded three each CRs and PRs of 18 treated ATC patients (PR+CR: 5% vs. 33%; $p < 0.03$). Median survival in ATC was only 2.7 months, but two responses to doxorubicin plus cisplatin were durable at 41.3 and 34.7 months, suggesting a possible impact on survival in select patients with ATC.

First-line therapy. At the time of the formulation of these guidelines the agents with the greatest established clinical activity in metastatic ATC are the taxanes paclitaxel or docetaxel, the anthracycline doxorubicin, and perhaps also platins. None of these agents, however, have proven ability to extend survival or quality of life in advanced ATC. Depending upon the directives of a particular patient and patient characteristics that might otherwise affect decision making, first-line therapy in advanced ATC could reasonably include these drugs as single agents or alternatively in combination. Alternatively, a clinical trial should be considered if available. Table 6 provides examples of chemotherapy regimens in advanced ATC.

Second-line or salvage therapy. Similarly, no prospective data are available to guide decision making in choosing second-line or subsequent salvage systemic therapy in advanced ATC. Consequently, patient directives or preferences and the prior response data in a particular patient should heavily inform decision making. For instance, should a particular patient respond especially well to first-line paclitaxel therapy but progress, consideration could be given to salvage therapy using another anti-microtubule agent (e.g., ixabepilone, combretastatin/crolibulin on a clinical trial). However, since no prospective data are available to guide second-line therapy, strong consideration should be given to enrollment in clinical trials.

Approaches to systemic disease (novel or investigational)

Unfortunately, there are no systemic therapeutics (cytotoxic, novel, targeted, or otherwise) of proven benefit in terms of improved survival and/or quality of life in advanced ATC. Consequently, there is critical need to develop novel systemic therapeutic approaches, and all patients wishing an aggressive approach to their cancer who are of sufficient vigor and performance status should therefore be considered as candidates for therapeutic clinical trials. However, suitable trials may not always be available to or practical for a particular patient, justifying use of available therapeutics in the non-study setting in some circumstances.

A number of novel agents have been preliminarily studied in ATC. Fosbretabulin, a prodrug of the investigational antimicrotubule disrupting agent combretastatin, was assessed in a phase II trial in ATC, producing no PRs or CRs in ATC patients. However, stable disease was seen in 7 of 26 patients with a median survival of 4.7 months and 23% of patients surviving 1 year (192). Its parent compound, combretastatin, has also shown preliminary activity anecdotally in a single ATC patient treated in a phase I trial of the agent (192,193), with a related compound, crolibulin, also being evaluated in ongoing clinical trials in ATC. Sorafenib, a multitargeted tyrosine kinase inhibitor that weakly inhibits the *BRAF* gene product and more potently inhibits angiogenesis via inhibition of vascular endothelial growth factor receptors has also been assessed in a small number of ATC patients in two recent phase II clinical trials, with no RECIST responses seen in six treated patients (194,195). Likewise, in a trial of all thyroid cancer histotypes, the tyrosine kinase inhibitor axitinib also yielded no responses in two treated ATC patients (196). Gefitinib, an epidermal growth factor receptor-targeted kinase inhibitor similarly produced no responses in five treated ATC patients although one had stable disease for 12 months (197). However, in a trial of the kinase inhibitor imatinib, two of eight evaluable patients attained a partial response, with stable disease reported in an additional four patients; 6-month progression-free survival was 36% with 6-month overall survival somewhat encouraging at 45% (198). These preliminary data suggest that novel antimicrotubule inhibitors and kinase inhibitors may ultimately find application as useful ATC therapeutics.

TABLE 6. EXAMPLES OF CHEMOTHERAPY REGIMENS IN ADVANCED ANAPLASTIC THYROID CARCINOMA

Regimen	Agents/dosages	Frequency
Paclitaxel/carboplatin	Paclitaxel 60–100 mg/m ² , carboplatin AUC 2 mg/m ² IV	Weekly
Paclitaxel/carboplatin	Paclitaxel 135–175 mg/m ² , carboplatin AUC 5–6 mg/m ² IV	Every 3–4 weeks
Docetaxel/doxorubicin	Docetaxel 60 mg/m ² IV, doxorubicin 60 mg/m ² IV (w/ pegfilgrastim)	Every 3–4 weeks
	Docetaxel 20 mg/m ² IV, doxorubicin 20 mg/m ² IV	Weekly
Paclitaxel	Paclitaxel 60–90 mg/m ² IV	Weekly
Paclitaxel	Paclitaxel 135–200 mg/m ² IV	Every 3–4 weeks
Doxorubicin	Doxorubicin 60–75 mg/m ² IV	Every 3 weeks
Doxorubicin	Doxorubicin 20 mg/m ² IV	Weekly

■ RECOMMENDATION 43

Since systemic therapy can result in transient, and occasionally more durable, disease regression or control in patients with advanced ATC and may improve survival in responders, it can reasonably be considered in patients with metastatic ATC of good performance status wishing an aggressive approach.

Strength of Recommendation: Strong

Quality of Evidence: Low

■ RECOMMENDATION 44

Patients with advanced or metastatic ATC wishing an aggressive approach should be encouraged to participate in clinical trials given the rarity of ATC, lack of data in support of improved survival or quality of life from any systemic therapeutics, and the need to develop evidence-based safe and effective therapeutic approaches in advanced ATC.

Strength of Recommendation: Strong

Quality of Evidence: Low

■ RECOMMENDATION 45

Combination or monotherapy including a taxane and/or an anthracycline could be considered in metastatic ATC if a suitable clinical trial is not otherwise available.

Strength of Recommendation: Strong

Quality of Evidence: Moderate

■ RECOMMENDATION 46

Since aggressive tumor-directed therapy may not be desired by or appropriate for all patients with metastatic ATC, consideration of best supportive care or hospice should also be prominently discussed as an alternative to systemic cancer-directed therapy.

Strength of Recommendation: Strong

Quality of Evidence: Low

Systemic therapy: what is next?

As anthracyclines (doxorubicin) and taxanes (paclitaxel, docetaxel) have at least some degree of clinical activity in advanced ATC, first-line ATC therapeutic clinical trials could reasonably include one of these agents so as to assure that use of a potentially effective therapy is not withheld or delayed. In this respect, two-arm trial designs comparing doxorubicin or paclitaxel alone to paclitaxel or doxorubicin combined with another candidate ATC therapeutic (showing evidence of preclinical synergy) have particular appeal. Available but sparse preclinical data suggest that agents targeting angiogenesis, mutant p53, EGFR, aurora kinases, and *PPAR γ* among others may represent reasonable candidate agents to consider in the salvage setting, perhaps especially when combined with cytotoxic chemotherapy.

Approaches to brain metastases

Brain metastases are relatively unusual in ATC, occurring in ~1%–5% of patients clinically, but they are associated with a poor prognosis (14,15,101,199). Chiu *et al.* (200) studied 47 cases of all types of thyroid cancer that had been metastatic to the brain. Brain metastases were most commonly detected during the monitoring of the patient after the original diagnosis of thyroid cancer, and brain metastases were the initial manifestation of thyroid cancer in 15% of patients. Patients

with brain metastases tended to be older and had more aggressive disease and accounted for 11 of the 47 patients (23%) that had ATC. Among the ATC patients with brain metastases, 56% had local regional invasion and 89% had locoregional cervical node involvement. The median time interval from the diagnosis of ATC to the diagnosis of brain metastases was 0.7 years, and the median time interval from diagnosis of brain lesions to death was 1.3 months. Disease-specific mortality was 100%. Salvati *et al.* (199) reported solitary brain metastases in 12 patients with thyroid cancer, five of whom had ATC. Four of five patients with ATC had lung and/or brain metastases, and median size of brain metastases in the ATC patients was 4 cm. All patients were treated with surgical removal and radiotherapy. The median survival of the five patients with ATC was 9 months (individual survival in months: 7, 8, 9, 10, 10).

Brain MRI and CT scans are more sensitive in detecting lesions than PET scans, with some evidence suggesting that brain MRI is more sensitive than CT scan (199,201).

■ RECOMMENDATION 47

Patients considering therapy should have radiologic studies (MRI or CT scan) assessing the presence of brain metastases when ATC is diagnosed. Additional radiologic studies of the brain are indicated in the context of progressive disease and/or neurological abnormalities suggesting the development of a brain lesion or change in character or size of a known brain lesion.

Strength of Recommendation: Strong

Quality of Evidence: Moderate

Salvati *et al.* (199) found a statistically significant improvement in survival ($p=0.03$) in ATC patients undergoing total removal of brain metastases as compared with patients undergoing subtotal removal. However, the number of patients studied was small, being three for total removal (survival 9, 10, and 10 months) and two for subtotal removal (survival 7 and 8 months). Surgical treatment resulted in improvement in quality of life and improvement in neurological symptoms. Sample size was very small and selection bias may be a significant issue in this study; therefore, these data must be interpreted carefully.

There are insufficient data to make a recommendation for or against Gamma Knife therapy in patients with ATC and metastases (200). Single small solitary brain metastases can be treated with radiosurgery such as Gamma Knife or undergo surgical resection. To be considered carefully in the decision-making process, however, is whether other systemic disease is imminently threatening coupled with consideration of the goals of the patient. Multiple lesions should instead be treated with whole-brain radiation therapy.

■ RECOMMENDATION 48

Surgical removal of brain lesion(s) in selected patients and/or radiation therapy may result in better disease control.

Strength of Recommendation: Weak

Quality of Evidence: Low

There is evidence that tyrosine kinase inhibitors are capable of crossing the blood–brain barrier, but there are insufficient studies to indicate that these agents are effective in treating brain metastases from ATC or whether they may be

detrimental by causing increased risk of bleeding in brain metastases (202,203).

There are no prospective, randomized clinical studies assessing the role of exogenous corticosteroid administration in patients with brain metastases from ATC. Therefore, recommendations are extrapolated from studies or guidelines regarding other tumors that have metastasized to the brain.

Ryken *et al.* (204) published guidelines for patients with brain metastases from a variety of different tumors. They noted there was insufficient evidence to recommend that patients with asymptomatic brain metastases without mass effect receive exogenous corticosteroids routinely. However, they recommended that patients with brain metastases with mass effect causing mild symptoms receive corticosteroids to attempt to give partial relief of cranial symptoms associated with increased intracranial pressure and edema. They recommended 4–8 mg/d of dexamethasone be considered as the initial dose. Patients with moderate to severe cranial symptoms should be considered to receive 16 mg/d (generally 4 mg, 4 times daily) (204). Dexamethasone is considered the preferred corticosteroid therapy in these circumstances. Dexamethasone should be tapered slowly over 2 weeks, but there should be individualization in that longer periods of dexamethasone can be considered in patients with severe disease who remain symptomatic. It is recommended that there be discussion of the long-term issues regarding corticosteroid administration. There are insufficient studies to render specific recommendations for patients regarding metastatic ATC to the brain. However, it is presently believed that the pathophysiology, approach, and treatment of brain metastases from any cause are similar and that similar treatment recommendations would apply.

■ RECOMMENDATION 49

Neurologically asymptomatic patients with brain metastases do not routinely require exogenous corticosteroid administration. Patients with neurologic brain compressive symptoms or signs should preferably receive dexamethasone (or alternatively a glucocorticoid equivalent) at appropriate doses. Individual patient considerations should apply with regard to the initiation, dose, and duration of exogenous corticosteroid administration.

Strength of Recommendation: Strong

Quality of Evidence: Moderate

Mikkelsen *et al.* (205) provided guidelines that did not recommend routine prophylactic use of antiseizure medications for adult patients with brain metastases that have not yet had a seizure. There is a paucity of relevant controlled studies. A single underpowered randomized controlled trial did not detect a statistically significant difference in seizure activity in patients who prophylactically received antiseizure medication and those that did not (206).

■ RECOMMENDATION 50

It is not recommended that patients with brain metastases from ATC routinely receive prophylactic antiseizure medications.

Strength of Recommendation: Weak

Quality of Evidence: Low

Approaches to bone metastases

ATC does metastasize to bone (~5%–15% of cases), usually in the presence of multiple other sites of distant metastases (14,15,101,207). Tickoo *et al.* (207) studied 79 patients with a variety of different types of thyroid cancer who had osseous metastases. Ten (four men, six women; mean age at bone metastasis 58.1 years) of these 79 patients had anaplastic cancer (five were solely undifferentiated and five also had a well-differentiated component). All 10 patients with ATC had died within 3.8 years of the diagnosis of osseous metastases, and 6 of the 10 patients who had ATC died within the first year. The median survival of the 10 patients with ATC was 0.55 years. Lam *et al.* (59) studied 38 patients with ATC (7 men, 31 women), mean age 70 years (range 15–93 years). Eighteen patients had distant metastases, five of whom had osseous metastases. The five patients with osseous metastases ranged in age from 15 to 87 years and died 1 day after admission to 10 months after diagnosis. Pittas *et al.* (208) retrospectively reviewed 146 patients with thyroid cancer and bone metastases. Ten of these patients had undifferentiated cancer; their median survival was less than a year, and 3-year survival was ~20%.

Given the paucity of studies regarding the diagnosis and treatment of osseous metastases in patients with ATC, it is reasonable to consider relevant recommendations in patients with cancers with more frequent osseous metastases. In this regard, there are three primary issues: (i) how to best treat symptomatic and/or threatening bony metastases, (ii) how to optimally undertake surveillance for additional metastases, and (iii) the role of systemic agents in preventing or slowing bony metastases.

With regard to therapy for symptomatic or threatening bony metastases, surgery or radiotherapy can be considered depending upon the situation. In general, radiation therapy is preferred in ATC unless surgery is absolutely required to preserve function (e.g., imminently threatening spinal cord compression, pathological long bone fracture). The generally dire prognosis for ATC lessens enthusiasm for aggressive surgical palliation, if avoidable. Newer approaches to palliation of bony metastases such as cryoablation may have a role also, but have been largely unexplored to date.

With regard to systemic therapy related to bony metastases, there are no available data specific to ATC. Nonetheless, Aapro *et al.* (209) reported the recommendation of an international committee related to systemic therapy for bony metastases for solid tumors in general. They reviewed the literature and noted that bisphosphonates are effective in preventing, inhibiting, and delaying cancer-associated skeletal complications. In summary, the committee recommended intravenous zoledronic acid therapy for patients with osseous metastases from solid tumors. Intravenous as opposed to oral bisphosphonates are preferred because data are largely unavailable on the roles of oral bisphosphonates in bone metastases. Patients must have recent (e.g., within 2–3 days) renal function and calcium assessments and routine initial and monitoring dental examinations with consideration of osteonecrosis as an infrequent adverse effect. Hortobagyi *et al.* (210) demonstrated that monthly IV infusion of pamidronate in patients with osseous metastases from breast cancer increased the time to the initial skeletal complication and decreased the percentage of patients with skeletal complications.

Zoledronic acid was associated with decreased skeletal complications in six patients with osseous metastases from thyroid cancer (209). The mechanisms of bone metastases occurring and propagating are complex but may be similar in different diseases (211,212).

Bisphosphonates, especially given intravenously, have potential side effects that include an acute-phase reaction and posttherapy bony pains, hypocalcemia, and rarely osteonecrosis of the jaw. There is also a risk of atypical femoral fractures (213), but this risk is small compared to benefits in patients with bony metastases. Bisphosphonates should be administered cautiously to patients with renal disease and should not be administered to patients with a creatinine clearance 35 mL/min or less or to patients with hypocalcemia, vitamin D deficiency, or a history of allergy to bisphosphonates (213). Bisphosphonate dosage should also be corrected based upon renal function and dosages held for hypocalcemia.

Denosumab, an inhibitor of receptor activator of nuclear factor B ligand (RANK ligand) is also effective in decreasing skeletal events in patients with osseous metastatic cancer and in some settings is more effective than intravenous bisphosphonates (214). Complications of the two classes of agents are relatively similar (214). At present, there are insufficient published studies specifically regarding ATC to substantiate its use in this disease, but the mechanisms of bone metastasis development and progression may be similar in various diseases.

Once bony metastases are noted, surveillance for additional metastases becomes important. Priority should be given to detection of threatening lesions where they can do the greatest harm—most often spine, long bones, and related areas (e.g., acetabulum). Imaging techniques are constantly evolving, and the most sensitive and specific method to diagnose osseous metastases will vary with the individual tumor involved, the osseous site of metastases, whether the patient is symptomatic and if a specific area is being considered, or whether the purpose of the study is for screening the skeleton in a patient with a high likelihood of osseous metastases (208,215–217). Given these caveats, a skeletal survey with plain radiographs to include long bones may be used to screen the skeleton. ATC osseous lesions are mainly osteolytic in nature. Since ^{99m}Tc methylene diphosphonate mainly detects osteoblastic lesions, this technique has less sensitivity and specificity than other available radiologic techniques (217). MRI and CT scans are excellent for identifying bone lesions in a specific site but are less useful for general skeletal screening, although whole body MRI is a newer technique (215). CT scans combined with ¹⁸F-FDG PET scans are very helpful in identifying osseous lesions and screening the skeleton but are expensive (215).

Bone metastases causing pain can be effectively alleviated with a course of palliative radiotherapy, typically performed over 1–2 weeks with 5–10 equal daily fractions of 300–400 cGy to a total dose of 2000–3000 cGy. A single fractionation of 800 cGy may also be appropriate. In the setting of metastases involving weight-bearing bones, orthopedic fixation of fracture due to metastasis should be considered. Long bone fractures most commonly involve the femur and humerus and are typically first internally fixed by intramedullary devices that control impaction, distraction, and stress by the use of proximal and distal interlocking fixation devices (218,219). These techniques allow weight-bearing ambulation. Palliative radiotherapy can be administered after orthopedic fixation to further promote pain relief without the fear of exacerbating

the fracture. A similar concept is also seen with decompressive surgical intervention in the setting of spinal cord compression caused by metastatic cancer. A recent randomized trial has shown that direct decompressive surgery plus postoperative radiotherapy is superior to radiotherapy alone in the treatment of spinal cord compression secondary to metastatic disease (218,219).

■ RECOMMENDATION 51

Patients with ATC who during the course of monitoring and treatment have skeletal symptoms, such as pain or pathologic fracture, should have radiologic evaluation of the specific area of concern. If there is proven osseous metastasis at a single specific site, radiologic evaluation of the skeleton may be performed to identify other sites of bony metastases.

Strength of Recommendation: Strong
Quality of Evidence: Low

■ RECOMMENDATION 52

It is reasonable to treat osseous metastases from ATC in a comparable manner to patients with other aggressive tumors causing osseous metastases with emphasis on radiotherapy and/or surgery. Metastatic lesions to the bone should be considered for palliative radiotherapy. If the lesions are in a weight-bearing region, orthopedic fixation should be considered prior to initiation of palliative radiotherapy.

Strength of Recommendation: Strong
Quality of Evidence: Low

■ RECOMMENDATION 53

Patients with known osseous metastases from ATC should be considered for periodic intravenous bisphosphonate infusions or subcutaneous RANK ligand inhibitor. Given the lack of data, it is not possible to make a definitive recommendation regarding the frequency and duration of these treatments.

Strength of Recommendation: Weak
Quality of Evidence: Low

Approaches to other sites of metastases

Thyroid cancers including ATC can metastasize to any site, and therapy needs to be individualized to metastatic locations, much as would be the case for other malignancies. Several additional “special cases” related to metastatic sites also deserve comment, including lung, liver, and skin.

Lung metastases are quite common in advanced ATC. Unfortunately, most patients with lung metastases have numerous metastases that cannot be effectively resected or treated with stereotactic radiation approaches. However, some patients develop symptomatic metastases to pleura or chest wall that can be palliated using radiotherapy. Occasionally, central mediastinal nodal metastases arise that compress bronchi and threaten postobstructive pneumonia. Under such circumstances, palliative radiotherapy should be considered. Endobronchial lesions causing hemoptysis can be palliated using endobronchial therapy such as laser or by radiotherapy.

Liver metastases in ATC are often numerous, similarly making directed therapy impractical in most patients. In rare

situations, however, patients can develop a few liver metastases in the absence of other threatening systemic disease. As in other cancers metastatic to liver, focal palliation with radiofrequency ablation or stereotactic body radiosurgery can be considered in such patients.

Thyroid cancer metastases to skin are rare. Dahl *et al.* (220) reported 43 patients with skin metastases from thyroid cancer (all types). Papillary thyroid cancer accounted for 41%, follicular cancer 28%, ATC 15%, and MTC 15%. Given its rarity compared to the other types, it would appear that ATC has a greater tendency to metastasize to cutaneous sites than the other types of thyroid cancer. The scalp was the most common site of cutaneous metastases (220). The vast majority of patients with cutaneous metastases had known disseminated thyroid cancer. Capezzone *et al.* (221) reported a single patient that had cutaneous metastases from ATC 4 months after thyroidectomy, and these cutaneous metastases were the first sign of distant disease.

Cutaneous metastases should be approached in the customary manner by FNA, core biopsy, or preferably excisional biopsy or removal if feasible with appropriate histologic examination and stains. All patients with ATC should have a periodic skin examination with special attention to areas of patient concerns. The treatment of cutaneous metastases depends on the clinical situation. If the cutaneous abnormality occurs in the setting of known widespread metastases, it may not be necessary to biopsy or remove the lesion. If the lesion represents an initial presentation or initial recurrence, a biopsy is required for a diagnosis. Excisional biopsy of the lesion is usually considered adequate treatment for the cutaneous manifestation.

Utility of cryoablation and selective embolization

Cryoablation is the application of low temperatures to a specific area of abnormal or cancerous tissue. There are insufficient reports to allow a definitive conclusion as to the role of cryoablation, radiofrequency ablation, and embolization in patients with ATC. Dedejus *et al.* (222) and Tazbir *et al.* (223) reported the utility of selective embolization of thyroid arteries in a total of 20 patients with thyroid cancer, seven of whom had ATC. Embolization was considered for patients with inoperable local disease with symptoms. Six patients with ATC had improvement in respiration, four had decreased local discomfort, two had disappearance of stridor, and two patients had decreased local tumor bleeding.

■ **RECOMMENDATION 54**

A definitive recommendation regarding cryoablation, radiofrequency ablation, and selective embolization in patients with ATC cannot be made.

Strength of Recommendation: Weak

Quality of Evidence: Insufficient

Approach to thrombosis and/or tumor invasion into vasculature

Seo *et al.* (224) studied 84 patients with 86 malignant thyroid tumors (of all types), each of whom had extracapsular extension. CT evaluation was able to identify invasion of the common carotid with a sensitivity of 75% and accuracy of 98.8% and of invasion of the internal jugular vein with a sensitivity and accuracy of 33.3% and 97.1%, respectively.

Panzironi *et al.* (225) used ultrasound to diagnose bilateral jugular vein thrombosis in a patient with ATC who had superior vena cava syndrome. Sugimoto *et al.* (226) also reported a patient with ATC that extended locally as well as into the left internal jugular vein, bilateral brachiocephalic veins, superior vena cava, and right atrium. CT and MRI demonstrated these abnormalities. Intra-atrial extension via the superior vena cava is rare, being reported in about 13 cases. Surgical removal of the tumor thrombus was attempted in six cases, generally with poor outcomes.

■ **RECOMMENDATION 55**

Tumor invasion into cervical veins can be diagnosed by CT, MRI, or venogram in the appropriate clinical context. There are insufficient data available to recommend either monitoring or a specific therapy such as surgery or radiation therapy for vascular tumor invasion.

Strength of Recommendation: Weak

Quality of Evidence: Low

In general, patients with various cancers are at higher risk for thrombosis (227). Relative indications for prophylactic anticoagulation include prolonged surgery, chemotherapy, long-term in-dwelling central venous lines, or prolonged immobility (227). The American Society of Clinical Oncology Guidelines (227) do not recommend prophylactic anticoagulation routinely in cancer patients who are ambulatory, with the notable exception of patients receiving thalidomide or lenalidomide. Hospitalization is considered an indication for prophylaxis for venous thromboembolism if the patient does not have active bleeding or other relevant contraindications. Major surgery is thought to be an indication for pharmacologic thromboprophylaxis. Patients with established venous thromboembolism should generally be treated with low molecular weight heparin with consideration of the individual context (227). There are inadequate studies assessing systemic anticoagulation in patients with ATC to form specific conclusions.

■ **RECOMMENDATION 56**

Consider prophylactic anticoagulation in patients who are at high risk for thromboembolic disease such as major surgery or receiving pertinent chemotherapy (specifically including thalidomide or lenalidomide).

Strength of Recommendation: Strong

Quality of Evidence: Moderate

■ **RECOMMENDATION 57**

Patients with documented venous thromboembolism should generally be treated with low molecular weight heparin with specific consideration of the individual context.

Strength of Recommendation: Strong

Quality of Evidence: High

PALLIATIVE CARE AND HOSPICE

There is a distinction between palliative care and hospice care. Although it is common for the terms to be used interchangeably, they are not the same services. Palliative care services focus on pain and symptom management at any point during the patient's treatment. A patient need not be diagnosed with a terminal condition in order to be

appropriate for palliative care services. Patients may be undergoing aggressive treatment for ATC and still be appropriate for a palliative care consult. Ultimately, palliative care consultation can be useful at any stage of a serious illness and can be provided at the same time as aggressive, life-prolonging treatment. On the other hand, hospice care focuses on pain and symptom management for patients who are no longer receiving life-prolonging therapies. Some states mandate that physicians involve palliative care expertise and discuss palliative care options when patients are diagnosed with terminal illnesses. In 2009, The Terminal Patients' Right to Know End-of-Life Options Act took effect in California (California Codes, Health and Safety Code Sections 442–442.7), while in 2011, The Palliative Care Information Act (Public Health Law section 2997-c) was passed in New York State. Such laws mean that failure to discuss palliative care options with terminally ill patients now violate state law. Although some critics (228) have pointed out that legally mandating such discussions is difficult in cases in which a terminal diagnosis is ambiguous, terminal illness is not ambiguous in ATC. Physicians practicing in states with palliative care laws would be required to involve palliative care expertise for their ATC patients.

Definition of a palliative care service

In an academic medical setting, a palliative care service is a multidisciplinary service that addresses physical, emotional, social, intellectual, and spiritual needs of the patient and family. Such services typically include one or more of the following: a medical practitioner specifically trained in palliative medicine; a nurse practitioner; and trained counselors to deal with patients and families coping with serious illness, life-limiting illnesses with no predictable endpoint, complications of therapies, or end-of-life situations. Palliative care is inclusive of life-prolonging therapies.

In the U.S. private practice setting, or a nonacademic setting, palliative care services are quite likely to be available in local hospitals, even in remote settings. As of 2009, >81% of facilities with 300 or more beds had a palliative care program, and 63% of facilities with >50 beds had palliative care programs. Not-for-profit and public hospitals were more likely to have a palliative care program than for-profit institutions. In most private practices—even in remote areas—a hospital close to the patient providing such services is usually available (119,229,230).

When to involve palliative care in ATC. Palliative care is useful at any point during the patient's treatment, and expertise from palliative care services may help the patient remain more active and comfortable in resuming daily activities. Additionally, physicians who may have difficulty addressing the patient's emotional, psycho-social, or spiritual anxieties about ATC can call upon palliative care experts to assist with these issues. In reference to specific patient management issues, such as pain control, nutrition, and airway preservation, see the appropriate sections in this document.

When to involve hospice care in ATC. When patients decline therapies intended to prolong life, yet desire dignity and quality of life for end-of-life care spanning the remainder of their illness, hospice care is appropriate. In such cases, the same palliative care teams or services are called in but are

specifically provided with a "hospice" goal. In such cases, pastoral expertise or support may also be provided to patients and families, as well as hospice options. Hospice care is frequently undertaken within the patient's home; however, in some cases, a hospice facility may provide the best setting.

Working effectively with a palliative care or hospice care team. Practitioners managing ATC patients should not "abandon" their patients to palliative care or hospice care teams. Rather, one of the patient's physicians should serve to coordinate this care. Such a physician could be the oncologist, endocrinologist, or primary care physician, depending upon patient preferences, relationships with practitioners, and logistic concerns. The patient might still require a multi-team level of care or may choose to utilize the expertise of a single physician.

RECOMMENDATION 58

The treatment team should include palliative care expertise at every appropriate stage of patient management to help with pain and symptom control, as well as addressing psychosocial and spiritual issues. Palliative care services are appropriate for any ATC patient receiving treatment intended to prolong life.

Strength of Recommendation: Strong

Quality of Evidence: Low

RECOMMENDATION 59

The treatment team should engage hospice care for ATC patients who decline therapies intended to prolong life, yet still require symptom and pain relief spanning the remainder of their illness.

Strength of Recommendation: Strong

Quality of Evidence: Low

SURVEILLANCE AND LONG-TERM MONITORING

Despite our best initial therapeutic efforts, the majority of patients with ATC will have disease progression within a few months' time. When calculated using a weighted average approach to the data provided in Table 7, 65.8% of patients develop distant metastases at some point during follow-up (33.5% of patients having distant metastases identifiable at diagnosis and 32.3% developing newly identified distant metastases usually within the first 6–12 months of follow-up; see Table 7) (15,58,59,113,156,161,162,167,168,176,231–233). Distant metastases are most frequently detected in the lungs (~80%–85%), followed by the bones (~5%–10%), and the brain (~5%–10%) (15,58,59,101,167,233).

Respiratory insufficiency (pulmonary metastases, pneumonia, or pulmonary fibrosis) was the most common, identifiable cause of death in patients with fatal ATC (234). At the time of death from ATC, 34% had locoregional disease without distant metastases, while 24% had distant metastases alone, and 40% had both locoregional and distant disease (234).

Furthermore, failure of locoregional control is seen in 17%–41% of patients by 3 months, 35%–83% by 6 months, and 92% by 8 months of follow-up (58,167,168,235). Even in patients that have gross resection of the anaplastic primary, 38% of the R0 resections and 36% of the R1 resections have local disease progression at a median of 2.5 months follow-up (58). In this

TABLE 7. PERCENT OF ANAPLASTIC PATIENTS WITH DISTANT METASTASES

Reference	N	Metastatic disease identified at diagnosis (%)	New metastatic disease identified during follow-up (%)	Metastatic disease at any time (%)
McIver <i>et al.</i> , 2001 (58)	134	46	22	68
Wang <i>et al.</i> , 2006 (168)	47	17	34	51
Swaak-Kragten <i>et al.</i> , 2009 (156)	75	40	35	75
Rodriguez <i>et al.</i> , 2000 (231)	14	21	27	48
Lam <i>et al.</i> , 2000 (59)	38	—	—	47
Schlumberger <i>et al.</i> , 1991 (162)	20	45	20	65
Kim and Leeper, 1987 (232)	19	32	47	79
Levendag <i>et al.</i> , 1993 (167)	51	43	32	75
Busnardo <i>et al.</i> , 2000 (176)	29	76	21	97
De Crevoisier <i>et al.</i> , 2004 (161)	30	20	43	63
Venkatesh <i>et al.</i> , 1990 (15)	121	11	42	53
Hadar <i>et al.</i> , 1993 (233)	55	—	—	42
Demeter <i>et al.</i> , 1991 (113)	7	—	—	57

series, external beam irradiation was associated with a slight, but not statistically significant delay in time to locoregional failure from 3 to 5 months ($p=0.08$) (58).

These data indicate that cross-sectional imaging at frequent, early intervals is required to determine the response to additional therapy and to identify new sites of disease that may necessitate a change in the management plan. The frequency and intensity of follow-up studies is guided by both the stage at diagnosis and an assessment of individual response to initial therapy.

Surveillance after clinical remission

After initial staging and completion of initial therapy, if the patient has no clinical evidence of disease, cross-sectional imaging of the brain, neck, chest, abdomen, and pelvis should be considered every 1–3 months for the first 6–12 months, then every 4–6 months for 1 additional year in patients desiring ongoing aggressive management. Additional imaging studies should be ordered based on specific symptoms that develop during follow-up. Alternatively, patients can be followed without extensive cross-sectional imaging if the patient is not interested in aggressive therapy for asymptomatic recurrent disease. If there is no evidence of recurrence on cross-sectional imaging during the first 2 years of follow-up, cross-sectional imaging can then be done less frequently, at 6- to 12-month intervals for an additional 2–3 years. For patients with persistent structural disease (either locoregional disease or distant metastases), cross-sectional imaging of brain, neck, chest, abdomen, pelvis, and known sites of disease should be obtained as clinically indicated (usually every 2–3 months) to judge response to systemic and/or local therapy.

In addition to its role in initial staging, ^{18}F FDG PET scanning is also a valuable tool in the follow-up of patients with ATC. ^{18}F FDG PET/CT scanning has a higher sensitivity for detection of metastatic lesions than CT alone (99.6% vs. 62% in identifying 265 individual lesions in 18 patients, $p<0.002$) (98). It is important that the CT be done with the PET scan because very small volume pulmonary metastases can be seen with the CT that are below the limit of resolution of the PET scan (98). Furthermore, ^{18}F FDG PET scan findings alter management recommendations in 25%–50% of patients (95,98). When used

in the follow-up of previously treated patients, the PET/CT findings were discordant from the CT findings in 45% of the cases (5/11). In each discordant case, the ^{18}F FDG PET findings were more informative than response to therapy as determined by change in size described by the CT scan (98).

Therefore, ^{18}F FDG PET scanning should be considered approximately 3–6 months after initial therapy in patients with no clinical evidence of disease to rule out small foci of disease that would lead to additional therapy recommendations. ^{18}F FDG PET scanning may also be of value in the follow-up of patients with known persistent structural disease as a guide to response to systemic or local therapies and to identify new sites of disease that may require a modification of the treatment plan.

While serum Tg and RAI scanning and therapy can be valuable tools in the management of well-differentiated thyroid cancer, the failure of ATCs to either produce Tg or concentrate RAI makes these tools of little help in the follow-up of patients with ATC. Therefore, serum Tg and RAI scanning are not routinely used in the management of ATC. However, consideration for RAI ablation/therapy is warranted in long-term ATC survivors if a significant component of the tumor was well differentiated since they may well have residual well-differentiated thyroid cancer metastases that could be RAI avid. Bone scintigraphy has been used in some patients in an effort to identify skeletal metastases. However, the sensitivity and specificity for detecting metastatic ATC is not well understood. ^{18}F FDG PET scanning identified the sites of disease in three ATC patients with bone metastases, while bone scintigraphy was abnormal in only one of the three patients (98). Therefore, it seems unlikely that bone scintigraphy will significantly improve staging done using ^{18}F FDG PET scanning. However, the role of bone scintigraphy and skeletal surveys as a staging or response to therapy evaluation in the absence of ^{18}F FDG PET scanning remains to be defined.

RECOMMENDATION 60

Following initial staging and therapy, patients without evidence for persistent structural disease desiring ongoing aggressive management should have cross-sectional imaging of the brain, neck (and/or ultrasound), chest,

abdomen, and pelvis at 1- to 3-month intervals for 6–12 months, then at 4- to 6-month intervals for a minimum of one additional year.

Strength of Recommendation: Strong
Quality of Evidence: Low

■ RECOMMENDATION 61

¹⁸F-DG PET scanning should be considered about 3–6 months after initial therapy in patients with no clinical evidence of disease to identify small volume disease that may require a change in the management plan. Furthermore, ¹⁸F-DG PET scanning should also be considered at 3- to 6-month intervals in patients with persistent structural disease as a guide to the response to therapy and to identify new sites of disease that may necessitate a change in the management plan.

Strength of Recommendation: Strong
Quality of Evidence: Low

■ RECOMMENDATION 62

Neither serum Tg measurements nor RAI scanning or therapy are recommended in the initial management of ATC unless the anaplastic component represents a minor component of a more well-differentiated thyroid cancer.

Strength of Recommendation: Strong
Quality of Evidence: Low

■ RECOMMENDATION 63

After a 6- to 12-month follow-up period, patients without evidence of recurrent/progressive ATC should be considered for RAI therapy if the original tumor had well-differentiated thyroid cancer components.

Strength of Recommendation: Strong
Quality of Evidence: Low

Restaging of patients with persistent metastatic disease

Restaging of individual patients with persistent advanced ATC should be tailored to the pace of disease progression, the involved sites of known disease and, most especially, emerging patient symptoms. Also of critical consideration in surveillance is the particular patient's chosen approach to advanced disease. Those patients desiring continued antitumor therapy need assessments frequently enough to evaluate their response. Patients not receiving antitumor therapy may select symptom-directed rather than routine cross-sectional imaging.

■ RECOMMENDATION 64

Patients with persistent structural disease following initial staging and therapy should have frequent cross-sectional imaging (at least every 1–3 months), which may include brain, neck, chest, abdomen, pelvis, and known sites of disease as clinically indicated to guide systemic and/or local therapy.

Strength of Recommendation: Strong
Quality of Evidence: Low

■ RECOMMENDATION 65

Patients with persistent structural disease following initial staging and therapy who wish to minimize additional

therapy may undergo symptom-directed cross-sectional imaging.

Strength of Recommendation: Strong
Quality of Evidence: Low

SUMMARY

Patients who present with a rapidly expanding neck mass require rapid histopathologic confirmation of the diagnosis. If ATC is diagnosed, the patient's overall clinical status and TNM stage of the tumor should be determined. Treatment goals (aggressive versus supportive care) should be established by disclosing the status and risks/benefits, discussing the patient's values and preferences, and then having the patient make an informed decision. Patients with stage IVA/IVB resectable disease have the best long-term survival, particularly if a multimodal approach (surgery, IMRT for locoregional control, and systemic therapy) is used. Patients with unresectable stage IVB disease may also respond to aggressive multimodal therapy. Patients with distant metastases (stage IVC) only rarely have responded to traditional therapies, and if an aggressive approach is desired by the patient, a clinical trial should be considered. Hospice or palliative care is also an important component of managing patients with stage IVC disease. Readers interested in a complete list of our recommendations should consult the Supplementary Data.

ACKNOWLEDGMENTS

We wish to thank Ms. Kathleen Norton (Mayo Clinic, Jacksonville, FL) for her invaluable editorial assistance in preparation of this document. We gratefully acknowledge financial contributions to this project from the Thyroid Cancer Survivors Association and from Joan Shey of the Light of Life Foundation.

AUTHOR DISCLOSURE STATEMENT

J.D.B. is a consultant for OXiGENE, Inc. (South San Francisco, CA). K.D.B. is a consultant for UpToDate, Inc. (Waltham, MA) and Medscape WebMD LLC (New York, NY), and received clinical research support from Pfizer, Inc. (New York, NY), Eisai Inc. (Woodcliff Lake, NJ), Amgen Inc. (Thousand Oaks, CA), and Genzyme Corp. (Cambridge, MA). M.H.S. received clinical research support from Daiichi Sankyo, Inc. (Parsippany, NJ). R.C.S. received research support from Daiichi Sankyo for a clinical trial. R.M.T. received research support from Genzyme and is a consultant for Novo Nordisk (Princeton, NJ), AstraZeneca (Waltham, MA), VeracYTE (South San Francisco, CA), and Genzyme. K.B.A., S.L.A., K.C.B., E.K., N.L., Y.E.N., M.S.R., and A.R.S. have no financial disclosures.

REFERENCES

- Smallridge RC, Copland JA 2010 Anaplastic thyroid carcinoma: pathogenesis and emerging therapies. *Clin Oncol* 22:486–497.
- Passler C, Scheuba C, Prager G, Kaserer K, Flores JA, Vierhapper H, Niederle B 1999 Anaplastic (undifferentiated) thyroid carcinoma (ATC). A retrospective analysis. *Langenbecks Arch Surg* 384:284–293.
- Dijkstra B, Prichard RS, Lee A, Kelly LM, Smyth PP, Crotty T, McDermott EW, Hill AD, O'Higgins N 2007 Changing patterns of thyroid carcinoma. *Ir J Med Sci* 176:87–90.

4. Singer PA, Cooper DS, Daniels GH, Ladenson PW, Greenspan FS, Levy EG, Braverman LE, Clark OH, McDougall IR, Ain KV, Dorfman SG 1996 Treatment guidelines for patients with thyroid nodules and well-differentiated thyroid cancer. American Thyroid Association. *Arch Intern Med* **156**:2165–2172.
5. Cooper DS, Doherty GM, Haugen BR, Kloos RT, Lee SL, Mandel SJ, Mazzaferri EL, McIver B, Sherman SI, Tuttle RM 2006 Management guidelines for patients with thyroid nodules and differentiated thyroid cancer. *Thyroid* **16**: 109–142.
6. Cooper DS, Doherty GM, Haugen BR, Kloos RT, Lee SL, Mandel SJ, Mazzaferri EL, McIver B, Pacini F, Schlumberger M, Sherman SI, Steward DL, Tuttle RM 2009 Revised American Thyroid Association management guidelines for patients with thyroid nodules and differentiated thyroid cancer. *Thyroid* **19**:1167–1214.
7. Kloos RT, Eng C, Evans DB, Francis GL, Gagel RF, Gharib H, Moley JF, Pacini F, Ringel MD, Schlumberger M, Wells SA Jr 2009 Medullary thyroid cancer: management guidelines of the American Thyroid Association. *Thyroid* **19**:565–612.
8. Pitoia F, Ward L, Wohllk N, Friguglietti C, Tomimori E, Gauna A, Camargo R, Vaisman M, Harach R, Munizaga F, Corigliano S, Pretell E, Niepomnyszcz H 2009 Recommendations of the Latin American Thyroid Society on diagnosis and management of differentiated thyroid cancer. *Arq Bras Endocrinol Metabol* **53**:884–887.
9. National Comprehensive Cancer Network. NCCN Clinical Practice Guidelines in Oncology: Thyroid Carcinoma. Available at www.nccn.org/professionals/physician_gls/f_guidelines.asp#thyroid (accessed August 23, 2012).
10. Cobin RH, Gharib H, Bergman DA, Clark OH, Cooper DS, Daniels GH, Dickey RA, Duick DS, Garber JR, Hay ID, Kukora JS, Lando HM, Schorr AB, Zeiger MA 2001 AAACE/AAES medical/surgical guidelines for clinical practice: management of thyroid carcinoma. American Association of Clinical Endocrinologists. American College of Endocrinology. *Endocr Pract* **7**:202–220.
11. Qaseem A, Snow V, Owens DK, Shekelle P 2010 The development of clinical practice guidelines and guidance statements of the American College of Physicians: summary of methods. *Ann Intern Med* **153**:194–199.
12. Atkins D, Best D, Briss PA, Eccles M, Falck-Ytter Y, Flottorp S, Guyatt GH, Harbour RT, Haugh MC, Henry D, Hill S, Jaeschke R, Leng G, Liberati A, Magrini N, Mason J, Middleton P, Mrukowicz J, O'Connell D, Oxman AD, Phillips B, Schunemann HJ, Edejer TT, Varonen H, Vist GE, Williams JW Jr, Zaza S 2004 Grading quality of evidence and strength of recommendations. *BMJ* **328**:1490–1494.
- 12a. Edge SB, Byrd DR, Compton CC, Fritz AG, Greene FL, Trotti A (eds) 2010 *AJCC Cancer Staging Handbook: From the AJCC Cancer Staging Manual*, 7th ed. Springer-Verlag, New York.
13. Boerner S, Asa SL 2009 *Biopsy Interpretation of the Thyroid*. Lippincott Williams & Wilkins, Philadelphia, PA.
14. Carcangiu ML, Steeper T, Zampi G, Rosai J 1985 Anaplastic thyroid carcinoma. A study of 70 cases. *Am J Clin Pathol* **83**:135–158.
15. Venkatesh YS, Ordonez NG, Schultz PN, Hickey RC, Goepfert H, Samaan NA 1990 Anaplastic carcinoma of the thyroid. A clinicopathologic study of 121 cases. *Cancer* **66**:321–330.
16. Bronner MP, LiVolsi VA 1991 Spindle cell squamous carcinoma of the thyroid: an unusual anaplastic tumor associated with tall cell papillary cancer. *Mod Pathol* **4**:637–643.
17. Yoshida A, Kamma H, Asaga T, Masuzawa C, Kawahara S, Mimura T, Ito K 1992 Proliferative activity in thyroid tumors. *Cancer* **69**:2548–2552.
18. Ordonez NG, El-Naggar AK, Hickey RC, Samaan NA 1991 Anaplastic thyroid carcinoma. Immunocytochemical study of 32 cases. *Am J Clin Pathol* **96**:15–24.
19. Gaffey MJ, Lack EE, Christ ML, Weiss LM 1991 Anaplastic thyroid carcinoma with osteoclast-like giant cells. A clinicopathologic, immunohistochemical, and ultrastructural study. *Am J Surg Pathol* **15**:160–168.
20. Rosai J, Carcangiu ML, DeLellis RA 1992 Undifferentiated (anaplastic) carcinoma. In: Rosai J, Carcangiu ML, DeLellis RA (eds) *Tumors of the Thyroid Gland*, 3rd edition. Armed Forces Institute of Pathology, Washington, DC, pp 135–159.
21. Albores-Saavedra J, Henson DE, Glazer E, Schwartz AM 2007 Changing patterns in the incidence and survival of thyroid cancer with follicular phenotype—papillary, follicular, and anaplastic: a morphological and epidemiological study. *Endocr Pathol* **18**:1–7.
22. Seethala RR, Nikiforov YE 2009 Anaplastic (undifferentiated) carcinoma. In: Nikiforov YE, Biddinger PW, Thompson LDR (eds) *Diagnostic Pathology and Molecular Genetics of the Thyroid: A Comprehensive Guide for Practicing Thyroid Pathology*. Lippincott Williams & Wilkins, Philadelphia, PA, pp 228–248.
23. Wan SK, Chan JK, Tang SK 1996 Paucicellular variant of anaplastic thyroid carcinoma. A mimic of Reidel's thyroiditis. *Am J Clin Pathol* **105**:388–393.
24. Nishiyama RH, Dunn EL, Thompson NW 1972 Anaplastic spindle-cell and giant-cell tumors of the thyroid gland. *Cancer* **30**:113–127.
25. Canos JC, Serrano A, Matias-Guiu X 2001 Paucicellular variant of anaplastic thyroid carcinoma: report of two cases. *Endocr Pathol* **12**:157–161.
26. Albores-Saavedra J, Hernandez M, Sanchez-Sosa S, Simpson K, Angeles A, Henson DE 2007 Histologic variants of papillary and follicular carcinomas associated with anaplastic spindle and giant cell carcinomas of the thyroid: an analysis of rhabdoid and thyroglobulin inclusions. *Am J Surg Pathol* **31**:729–736.
27. Chetty R, Govender D 1999 Follicular thyroid carcinoma with rhabdoid phenotype. *Virchows Arch* **435**:133–136.
28. Albores-Saavedra J, Sharma S 2001 Poorly differentiated follicular thyroid carcinoma with rhabdoid phenotype: a clinicopathologic, immunohistochemical and electron microscopic study of two cases. *Mod Pathol* **14**:98–104.
29. Sumida T, Hamakawa H, Imaoka M, Okamoto N, Takarada M, Tanioka H, Ueda N, Nose M 2001 A case of submandibular malignant rhabdoid tumor transformed from papillary thyroid carcinoma. *J Oral Pathol Med* **30**:443–447.
30. Lai ML, Faa G, Serra S, Senes G, Daniele GM, Boi F, Mariotti S, Beauchemin M, Asa SL 2005 Rhabdoid tumor of the thyroid gland: a variant of anaplastic carcinoma. *Arch Pathol Lab Med* **129**:e55–57.
31. Sato K, Waseda R, Tatsuzawa Y, Soma R, Ueda Y, Katsuda S 2006 Papillary thyroid carcinoma with anaplastic transformation showing a rhabdoid phenotype solely in the cervical lymph node metastasis. *Pathol Res Pract* **202**:55–59.
32. Tobler A, Maurer R, Hedinger CE 1984 Undifferentiated thyroid tumors of diffuse small cell type. Histological and immunohistochemical evidence for their lymphomatous nature. *Virchows Arch A Pathol Anat Histopathol* **404**: 117–126.

33. Mambo NC, Irwin SM 1984 Anaplastic small cell neoplasms of the thyroid: an immunoperoxidase study. *Hum Pathol* **15**:55–60.
34. Sakamoto A, Kasai N, Sugano H 1983 Poorly differentiated carcinoma of the thyroid. A clinicopathologic entity for a high-risk group of papillary and follicular carcinomas. *Cancer* **52**:1849–1855.
35. Van der Laan BF, Freeman JL, Tsang RW, Asa SL 1993 The association of well-differentiated thyroid carcinoma with insular or anaplastic thyroid carcinoma; evidence for dedifferentiation in tumor progression. *Endocr Pathol* **4**:215–221.
36. Volante M, Collini P, Nikiforov YE, Sakamoto A, Kakudo K, Katoh R, Lloyd RV, LiVolsi VA, Papotti M, Sobrinho-Simoes M, Bussolati G, Rosai J 2007 Poorly differentiated thyroid carcinoma: the Turin proposal for the use of uniform diagnostic criteria and an algorithmic diagnostic approach. *Am J Surg Pathol* **31**:1256–1264.
37. Hiltzik D, Carlson DL, Tuttle RM, Chuai S, Ishill N, Shaha A, Shah JP, Singh B, Ghossein RA 2006 Poorly differentiated thyroid carcinomas defined on the basis of mitosis and necrosis: a clinicopathologic study of 58 patients. *Cancer* **106**:1286–1295.
38. Hurlimann J, Gardiol D, Scazziga B 1987 Immunohistology of anaplastic thyroid carcinoma. A study of 43 cases. *Histopathology* **11**:567–580.
39. Miettinen M, Franssila KO 2000 Variable expression of keratins and nearly uniform lack of thyroid transcription factor 1 in thyroid anaplastic carcinoma. *Hum Pathol* **31**:1139–1145.
40. Baloch ZW, LiVolsi VA 2008 Unusual tumors of the thyroid gland. *Endocrinol Metab Clin North Am* **37**:297–310, vii.
41. Makay O, Kaya T, Ertan Y, Icoz G, Akyildiz M, Yilmaz M, Tuncyurek M, Yetkin E 2008 Primary squamous cell carcinoma of the thyroid: report of three cases. *Endocr J* **55**:359–364.
42. Sanchez-Sosa S, Rios-Luna NP, Tamayo Bdel R, Simpson K, Albores-Saavedra J 2006 Primary squamous cell carcinoma of the thyroid arising in Hashimoto's thyroiditis in an adolescent. *Pediatr Dev Pathol* **9**:496–500.
43. Zhou XH 2002 Primary squamous cell carcinoma of the thyroid. *Eur J Surg Oncol* **28**:42–45.
44. Sutak J, Armstrong JS, Rusby JE 2005 Squamous cell carcinoma arising in a tall cell papillary carcinoma of the thyroid. *J Clin Pathol* **58**:662–664.
45. Kitahara S, Ito T, Hamatani S, Shibuya K, Shiba T 2006 Thyroid papillary carcinoma recurring as squamous cell carcinoma: report of a case. *Surg Today* **36**:171–174.
46. Moinuddin S, Barazi H, Moinuddin M 2008 Acute blastomycosis thyroiditis. *Thyroid* **18**:659–661.
47. Weiss IA, Limaye A, Tchertkoff V, Brener JL 1989 Sarcoidosis of the thyroid clinically mimicking malignancy. *NY State J Med* **89**:578–580.
48. LiVolsi VA, Brooks JJ, Arendash-Durand B 1987 Anaplastic thyroid tumors. Immunohistology. *Am J Clin Pathol* **87**:434–442.
49. Shvero J, Gal R, Avidor I, Hadar T, Kessler E 1988 Anaplastic thyroid carcinoma. A clinical, histologic, and immunohistochemical study. *Cancer* **62**:319–325.
50. Tacha D, Zhou D, Cheng L 2011 Expression of PAX8 in normal and neoplastic tissues: a comprehensive immunohistochemical study. *Appl Immunohistochem Mol Morphol* **19**:293–299.
51. Chang TC, Liaw KY, Kuo SH, Chang CC, Chen FW 1989 Anaplastic thyroid carcinoma: review of 24 cases, with emphasis on cytodiagnosis and leukocytosis. *Taiwan Yi Xue Hui Za Zhi* **88**:551–556.
52. Guarda LA, Peterson CE, Hall W, Baskin HJ 1991 Anaplastic thyroid carcinoma: cytomorphology and clinical implications of fine-needle aspiration. *Diagn Cytopathol* **7**:63–67.
53. Us-Krasovec M, Golouh R, Auersperg M, Besic N, Ruparcic-Oblak L 1996 Anaplastic thyroid carcinoma in fine needle aspirates. *Acta Cytol* **40**:953–958.
54. Giard RW, Hermans J 2000 Use and accuracy of fine-needle aspiration cytology in histologically proven thyroid carcinoma: an audit using a national pathology database. *Cancer* **90**:330–334.
55. Aldinger KA, Samaan NA, Ibanez M, Hill CS Jr 1978 Anaplastic carcinoma of the thyroid: a review of 84 cases of spindle and giant cell carcinoma of the thyroid. *Cancer* **41**:2267–2275.
56. LiVolsi VA 1990 *Surgical Pathology of the Thyroid*. W.B. Saunders, Philadelphia, PA.
57. Spires JR, Schwartz MR, Miller RH 1988 Anaplastic thyroid carcinoma. Association with differentiated thyroid cancer. *Arch Otolaryngol Head Neck Surg* **114**:40–44.
58. McIver B, Hay ID, Giuffrida DF, Dvorak CE, Grant CS, Thompson GB, van Heerden JA, Goellner JR 2001 Anaplastic thyroid carcinoma: a 50-year experience at a single institution. *Surgery* **130**:1028–1034.
59. Lam KY, Lo CY, Chan KW, Wan KY 2000 Insular and anaplastic carcinoma of the thyroid: a 45-year comparative study at a single institution and a review of the significance of p53 and p21. *Ann Surg* **231**:329–338.
60. Nikiforova MN, Kimura ET, Gandhi M, Biddinger PW, Knauf JA, Basolo F, Zhu Z, Giannini R, Salvatore G, Fusco A, Santoro M, Fagin JA, Nikiforov YE 2003 BRAF mutations in thyroid tumors are restricted to papillary carcinomas and anaplastic or poorly differentiated carcinomas arising from papillary carcinomas. *J Clin Endocrinol Metab* **88**:5399–5404.
61. Sugitani I, Kasai N, Fujimoto Y, Yanagisawa A 2001 Prognostic factors and therapeutic strategy for anaplastic carcinoma of the thyroid. *World J Surg* **25**:617–622.
62. Sugino K, Ito K, Mimura T, Nagahama M, Fukunari N, Kubo A, Iwasaki H, Ito K 2002 The important role of operations in the management of anaplastic thyroid carcinoma. *Surgery* **131**:245–248.
63. Ekman ET, Wallin G, Backdahl M, Lowhagen T, Auer G 1989 Nuclear DNA content in anaplastic giant-cell thyroid carcinoma. *Am J Clin Oncol* **12**:442–446.
64. Klemi PJ, Joensuu H, Eerola E 1988 DNA aneuploidy in anaplastic carcinoma of the thyroid gland. *Am J Clin Pathol* **89**:154–159.
65. Roque L, Soares J, Castedo S 1998 Cytogenetic and fluorescence in situ hybridization studies in a case of anaplastic thyroid carcinoma. *Cancer Genet Cytogenet* **103**:7–10.
66. Jenkins RB, Hay ID, Herath JF, Schultz CG, Spurbeck JL, Grant CS, Goellner JR, Dewald GW 1990 Frequent occurrence of cytogenetic abnormalities in sporadic non-medullary thyroid carcinoma. *Cancer* **66**:1213–1220.
67. Miura D, Wada N, Chin K, Magrane GG, Wong M, Duh QY, Clark OH 2003 Anaplastic thyroid cancer: cytogenetic patterns by comparative genomic hybridization. *Thyroid* **13**:283–290.
68. Wilkens L, Benten D, Tchinda J, Brabant G, Potter E, Dralle H, von Wasielewski R 2000 Aberrations of chromosomes 5 and 8 as recurrent cytogenetic events in anaplastic carcinoma of the thyroid as detected by fluorescence in situ

- hybridisation and comparative genomic hybridisation. *Virchows Arch* **436**:312–318.
69. Wreesmann VB, Ghossein RA, Patel SG, Harris CP, Schnaser EA, Shaha AR, Tuttle RM, Shah JP, Rao PH, Singh B 2002 Genome-wide appraisal of thyroid cancer progression. *Am J Pathol* **161**:1549–1556.
 70. Kitamura Y, Shimizu K, Tanaka S, Ito K, Emi M 2000 Allelotyping of anaplastic thyroid carcinoma: frequent allelic losses on 1q, 9p, 11, 17, 19p, and 22q. *Genes Chromosomes Cancer* **27**:244–251.
 71. Hunt JL, Tometsko M, LiVolsi VA, Swalsky P, Finkelstein SD, Barnes EL 2003 Molecular evidence of anaplastic transformation in coexisting well-differentiated and anaplastic carcinomas of the thyroid. *Am J Surg Pathol* **27**:1559–1564.
 72. Kadota M, Tamaki Y, Sekimoto M, Fujiwara Y, Aritake N, Hasegawa S, Kobayashi T, Ikeda T, Horii A, Monden M 2003 Loss of heterozygosity on chromosome 16p and 18q in anaplastic thyroid carcinoma. *Oncol Rep* **10**:35–38.
 73. Ito T, Seyama T, Mizuno T, Tsuyama N, Hayashi Y, Dohi K, Nakamura N, Akiyama M 1993 Genetic alterations in thyroid tumor progression: association with p53 gene mutations. *Jpn J Cancer Res* **84**:526–531.
 74. Rodrigues RF, Roque L, Rosa-Santos J, Cid O, Soares J 2004 Chromosomal imbalances associated with anaplastic transformation of follicular thyroid carcinomas. *Br J Cancer* **90**:492–496.
 75. Fagin JA, Matsuo K, Karmakar A, Chen DL, Tang SH, Koeffler HP 1993 High prevalence of mutations of the p53 gene in poorly differentiated human thyroid carcinomas. *J Clin Invest* **91**:179–184.
 76. Donghi R, Longoni A, Pilotti S, Michieli P, Della Porta G, Pierotti MA 1993 Gene p53 mutations are restricted to poorly differentiated and undifferentiated carcinomas of the thyroid gland. *J Clin Invest* **91**:1753–1760.
 77. Dobashi Y, Sugimura H, Sakamoto A, Mernyei M, Mori M, Oyama T, Machinami R 1994 Stepwise participation of p53 gene mutation during dedifferentiation of human thyroid carcinomas. *Diagn Mol Pathol* **3**:9–14.
 78. Ito T, Seyama T, Mizuno T, Tsuyama N, Hayashi T, Hayashi Y, Dohi K, Nakamura N, Akiyama M 1992 Unique association of p53 mutations with undifferentiated but not with differentiated carcinomas of the thyroid gland. *Cancer Res* **52**:1369–1371.
 79. Garcia-Rostan G, Camp RL, Herrero A, Carcangiu ML, Rimm DL, Tallini G 2001 Beta-catenin dysregulation in thyroid neoplasms: down-regulation, aberrant nuclear expression, and CTNNB1 exon 3 mutations are markers for aggressive tumor phenotypes and poor prognosis. *Am J Pathol* **158**:987–996.
 80. Garcia-Rostan G, Tallini G, Herrero A, D'Aquila TG, Carcangiu ML, Rimm DL 1999 Frequent mutation and nuclear localization of beta-catenin in anaplastic thyroid carcinoma. *Cancer Res* **59**:1811–1815.
 81. Kondo T, Ezzat S, Asa SL 2006 Pathogenetic mechanisms in thyroid follicular-cell neoplasia. *Nat Rev Cancer* **6**:292–306.
 82. Mochizuki K, Kondo T, Nakazawa T, Iwashina M, Kawasaki T, Nakamura N, Yamane T, Murata S, Ito K, Kamayama K, Kobayashi M, Katoh R 2010 RET rearrangements and BRAF mutation in undifferentiated thyroid carcinomas having papillary carcinoma components. *Histopathology* **57**:444–450.
 83. Sugg SL, Ezzat S, Zheng L, Freeman JL, Rosen IB, Asa SL 1999 Oncogene profile of papillary thyroid carcinoma. *Surgery* **125**:46–52.
 84. Smallridge RC, Marlow LA, Copland JA 2009 Anaplastic thyroid cancer: molecular pathogenesis and emerging therapies. *Endocr Relat Cancer* **16**:17–44.
 85. Buergy D, Weber T, Maurer GD, Mudduluru G, Medved F, Leupold JH, Brauckhoff M, Post S, Dralle H, Allgayer H 2009 Urokinase receptor, MMP-1 and MMP-9 are markers to differentiate prognosis, adenoma and carcinoma in thyroid malignancies. *Int J Cancer* **125**:894–901.
 86. Haas V, Celakovsky P, Brtkova J, Hornychova H 2008 Unusual manifestation of anaplastic thyroid cancer. *Acta Medica (Hradec Kralove)* **51**:233–236.
 87. Fujita T, Ogasawara Y, Naito M, Doihara H, Shimizu N 2006 Anaplastic thyroid carcinoma associated with granulocyte colony-stimulating factor: report of a case. *Surg Today* **36**:63–67.
 88. Sato T, Omura M, Saito J, Hirasawa A, Kakuta Y, Wakabayashi Y, Nishikawa T 2000 Neutrophilia associated with anaplastic carcinoma of the thyroid: production of macrophage colony-stimulating factor (M-CSF) and interleukin-6. *Thyroid* **10**:1113–1118.
 89. Alagol F, Tanakol R, Boztepe H, Kapran Y, Terzioglu T, Dizdaroglu F 1999 Anaplastic thyroid cancer with transient thyrotoxicosis: case report and literature review. *Thyroid* **9**:1029–1032.
 90. Heymann RS, Brent GA, Hershman JM 2005 Anaplastic thyroid carcinoma with thyrotoxicosis and hypoparathyroidism. *Endocr Pract* **11**:281–284.
 91. Iwai H, Ohno Y, Aoki N 2004 Anaplastic thyroid carcinoma with humoral hypercalcemia of malignancy (HHM): an autopsy case report. *Endocr J* **51**:303–310.
 92. Bjorkman MP, Sorva AJ, Tilvis RS 2009 Calculated serum calcium is an insufficient surrogate for measured ionized calcium. *Arch Gerontol Geriatr* **49**:348–350.
 93. Pfitzenmeyer P, Martin I, d'Athis P, Grumbach Y, Delmestre MC, Blonde-Cynober F, Derycke B, Brondel L 2007 A new formula for correction of total calcium level into ionized serum calcium values in very elderly hospitalized patients. *Arch Gerontol Geriatr* **45**:151–157.
 94. Loevner LA, Kaplan SL, Cunnane ME, Moonis G 2008 Cross-sectional imaging of the thyroid gland. *Neuroimaging Clin N Am* **18**:445–461, vii.
 95. Bogsrud TV, Karantanis D, Nathan MA, Mullan BP, Wiseman GA, Kasperbauer JL, Reading CC, Hay ID, Lowe VJ 2008 18F-FDG PET in the management of patients with anaplastic thyroid carcinoma. *Thyroid* **18**:713–719.
 96. Khan N, Oriuchi N, Higuchi T, Endo K 2005 Review of fluorine-18-2-fluoro-2-deoxy-D-glucose positron emission tomography (FDG-PET) in the follow-up of medullary and anaplastic thyroid carcinomas. *Cancer Control* **12**:254–260.
 97. Nguyen BD, Ram PC 2007 PET/CT staging and post-therapeutic monitoring of anaplastic thyroid carcinoma. *Clin Nucl Med* **32**:145–149.
 98. Poisson T, Deandreis D, Leboulleux S, Bidault F, Bonniaud G, Baillet S, Auperin A, Al Ghuzlan A, Travagli JP, Lumbroso J, Baudin E, Schlumberger M 2010 18F-fluorodeoxyglucose positron emission tomography and computed tomography in anaplastic thyroid cancer. *Eur J Nucl Med Mol Imaging* **37**:2277–2285.
 99. Samih N, Hovsepian S, Notel F, Prorok M, Zattara-Cannoni H, Mathieu S, Lombardo D, Fayet G, El-Battari A 2003 The impact of N- and O-glycosylation on the functions of Glut-1 transporter in human thyroid anaplastic cells. *Biochim Biophys Acta* **1621**:92–101.

100. Miyakoshi A, Dalley RW, Anzai Y 2007 Magnetic resonance imaging of thyroid cancer. *Top Magn Reson Imaging* **18**:293–302.
101. Tan RK, Finley RK 3rd, Driscoll D, Bakamjian V, Hicks WL Jr, Shedd DP 1995 Anaplastic carcinoma of the thyroid: a 24-year experience. *Head Neck* **17**:41–47; discussion 47–48.
102. Zhang ZM, Xu ZG, Tang PZ, Xue LY, Lu N 2006 [A retrospective analysis of anaplastic thyroid carcinoma]. *Zhongguo Yi Xue Ke Xue Yuan Xue Bao* **28**:322–324.
103. Besic N, Auersperg M, Us-Krasovec M, Golouh R, Frkovic-Grazio S, Vodnik A 2001 Effect of primary treatment on survival in anaplastic thyroid carcinoma. *Eur J Surg Oncol* **27**:260–264.
104. Higashiyama T, Ito Y, Hirokawa M, Fukushima M, Uruno T, Miya A, Matsuzuka F, Miyauchi A 2010 Induction chemotherapy with weekly paclitaxel administration for anaplastic thyroid carcinoma. *Thyroid* **20**:7–14.
105. Are C, Shaha AR 2006 Anaplastic thyroid carcinoma: biology, pathogenesis, prognostic factors, and treatment approaches. *Ann Surg Oncol* **13**:453–464.
106. Neff RL, Farrar WB, Kloos RT, Burman KD 2008 Anaplastic thyroid cancer. *Endocrinol Metab Clin North Am* **37**:525–538, xi.
107. Sherman S 2006 Anaplastic cancer: prognosis. In: Wartofsky L, Van Nostrand D (eds) *Thyroid Cancer: A Comprehensive Guide to Clinical Management*, 2nd edition. Humana Press, Totowa, NJ, pp 647–648.
108. Gilliland FD, Hunt WC, Morris DM, Key CR 1997 Prognostic factors for thyroid carcinoma. A population-based study of 15,698 cases from the Surveillance, Epidemiology and End Results (SEER) program 1973–1991. *Cancer* **79**:564–573.
109. Kim TY, Kim KW, Jung TS, Kim JM, Kim SW, Chung KW, Kim EY, Gong G, Oh YL, Cho SY, Yi KH, Kim WB, Park do J, Chung JH, Cho BY, Shong YK 2007 Prognostic factors for Korean patients with anaplastic thyroid carcinoma. *Head Neck* **29**:765–772.
110. Kebebew E, Greenspan FS, Clark OH, Woeber KA, McMillan A 2005 Anaplastic thyroid carcinoma. Treatment outcome and prognostic factors. *Cancer* **103**:1330–1335.
111. Akslen LA, Haldorsen T, Thoresen SO, Glatte E 1991 Survival and causes of death in thyroid cancer: a population-based study of 2479 cases from Norway. *Cancer Res* **51**:1234–1241.
112. Junor EJ, Paul J, Reed NS 1992 Anaplastic thyroid carcinoma: 91 patients treated by surgery and radiotherapy. *Eur J Surg Oncol* **18**:83–88.
113. Demeter JG, De Jong SA, Lawrence AM, Paloyan E 1991 Anaplastic thyroid carcinoma: risk factors and outcome. *Surgery* **110**:956–961; discussion 961–963.
114. Akaishi J, Sugino K, Kitagawa W, Nagahama M, Kamayama K, Shimizu K, Ito K 2011 Prognostic factors and treatment outcomes of 100 cases of anaplastic thyroid carcinoma. *Thyroid* **21**:1183–1189.
115. Ruhstaller T, Roe H, Thurlimann B, Nicoll JJ 2006 The multidisciplinary meeting: an indispensable aid to communication between different specialities. *Eur J Cancer* **42**:2459–2462.
116. Harrison JD, Choy ET, Spillane A, Butow P, Young JM, Evans A 2008 Australian breast cancer specialists' involvement in multidisciplinary treatment planning meetings. *Breast* **17**:335–340.
117. Sharma A, Sharp DM, Walker LG, Monson JR 2008 Colorectal MDTs: the team's perspective. *Colorectal Dis* **10**:63–68.
118. Blazeby JM, Wilson L, Metcalfe C, Nicklin J, English R, Donovan JL 2006 Analysis of clinical decision-making in multi-disciplinary cancer teams. *Ann Oncol* **17**:457–460.
119. Morrison RS, Meier DE 2004 Clinical practice. Palliative care. *N Engl J Med* **350**:2582–2590.
120. Teno JM, Lynn J 1996 Putting advance-care planning into action. *J Clin Ethics* **7**:205–213.
121. Miles SH, Koepp R, Weber EP 1996 Advance end-of-life treatment planning. A research review. *Arch Intern Med* **156**:1062–1068.
122. Fried TR, Bullock K, Iannone L, O'Leary JR 2009 Understanding advance care planning as a process of health behavior change. *J Am Geriatr Soc* **57**:1547–1555.
123. Levinsky NG 1996 The purpose of advance medical planning—autonomy for patients or limitation of care? *N Engl J Med* **335**:741–743.
124. Corcoran AM 2010 Advance care planning at transitions in care: challenges, opportunities, and benefits. *Annals of Long-Term Care: Clinical Care and Aging* **18**:26–29.
125. Wenger NS, Vespa PM 2010 Ethical issues in patient-physician communication about therapy for cancer: professional responsibilities of the oncologist. *Oncologist* **15**(Suppl 1):43–48.
126. Etchells E, Darzins P, Silberfeld M, Singer PA, McKenny J, Naglie G, Katz M, Guyatt GH, Molloy DW, Strang D 1999 Assessment of patient capacity to consent to treatment. *J Gen Intern Med* **14**:27–34.
127. Omnibus Budget Reconciliation Act of 1990, Sections 4206 and 4751, Public Law No. 101–508 (November 5, 1990).
128. Greco PJ, Schulman KA, Lavizzo-Mourey R, Hansen-Flaschen J 1991 The Patient Self-Determination Act and the future of advance directives. *Ann Intern Med* **115**: 639–643.
129. Pope TM 2011 Comparing the FHCDA to surrogate decision making laws in other states. *NYSBA Health Law Journal* **16**:107–111.
130. Etchells E, Sharpe G, Elliott C, Singer PA 1996 Bioethics for clinicians: 3. Capacity. *CMAJ* **155**:657–661.
131. Emanuel EJ, Emanuel LL 1992 Proxy decision making for incompetent patients. An ethical and empirical analysis. *JAMA* **267**:2067–2071.
132. Berger JT, DeRenzo EG, Schwartz J 2008 Surrogate decision making: reconciling ethical theory and clinical practice. *Ann Intern Med* **149**:48–53.
133. Etchells E, Sharpe G, Dykeman MJ, Meslin EM, Singer PA 1996 Bioethics for clinicians: 4. Voluntariness. *CMAJ* **155**:1083–1086.
134. Wenger NS 2005 Improving end of life decisions and pain management. Lecture delivered to University of Kentucky Program for Bioethics: April 12, 2005.
135. Rogers WA 1999 Beneficence in general practice: an empirical investigation. *J Med Ethics* **25**:388–393.
136. Pellegrino ED 1992 Beneficence, scientific autonomy, and self-interest: ethical dilemmas in clinical research. *Camb Q Healthc Ethics* **1**:361–369.
137. Emanuel EJ, Emanuel LL 1992 Four models of the physician-patient relationship. *JAMA* **267**:2221–2226.
138. Etchells E, Sharpe G, Burgess MM, Singer PA 1996 Bioethics for clinicians: 2. Disclosure. *CMAJ* **155**:387–391.
139. Etchells E, Sharpe G, Walsh P, Williams JR, Singer PA 1996 Bioethics for clinicians: 1. Consent. *CMAJ* **155**:177–180.
140. Childress JF, Meslin EM, Shapiro HT 2005 Belmont Revisited: Ethical Principles for Research with Human Subjects. Georgetown University Press, Washington, DC.

141. Levine RJ 1988 *Ethics and Regulation of Clinical Research*, 2nd edition. Yale University Press, New Haven, CT.
142. McClain CS, Rosenfeld B, Breitbart W 2003 Effect of spiritual well-being on end-of-life despair in terminally-ill cancer patients. *Lancet* **361**:1603–1607.
143. Ehman JW, Ott BB, Short TH, Ciampa RC, Hansen-Flaschen J 1999 Do patients want physicians to inquire about their spiritual or religious beliefs if they become gravely ill? *Arch Intern Med* **159**:1803–1806.
144. Rousseau P 2001 Existential suffering and palliative sedation: a brief commentary with a proposal for clinical guidelines. *Am J Hosp Palliat Care* **18**:151–153.
145. Emanuel LL 2008 Advance directives. *Annu Rev Med* **59**:187–198.
146. Silveira MJ, Kim SY, Langa KM 2010 Advance directives and outcomes of surrogate decision making before death. *N Engl J Med* **362**:1211–1218.
147. Venneman SS, Narnor-Harris P, Perish M, Hamilton M 2008 “Allow natural death” versus “do not resuscitate”: three words that can change a life. *J Med Ethics* **34**:2–6.
148. Bergman-Evans B, Kuhnel L, McNitt D, Myers S 2008 Uncovering beliefs and barriers: staff attitudes related to advance directives. *Am J Hosp Palliat Care* **25**:347–353.
149. Bishop JP, Brothers KB, Perry JE, Ahmad A 2010 Reviving the conversation around CPR/DNR. *Am J Bioeth* **10**:61–67.
150. Hamann AA 1993 Family surrogate laws: a necessary supplement to living wills and durable powers of attorney. *Villanova Law Rev* **38**:103–177.
151. Doukas DJ, McCullough LB 1991 The values history. The evaluation of the patient’s values and advance directives. *J Fam Pract* **32**:145–153.
152. Quill TE 2000 Perspectives on care at the close of life. Initiating end-of-life discussions with seriously ill patients: addressing the “elephant in the room”. *JAMA* **284**:2502–2507.
153. Jones JW, McCullough LB 2008 Just how far goes DNR? *J Vasc Surg* **48**:1630–1632.
154. Berry SR, Singer PA 1998 The cancer specific advance directive. *Cancer* **82**:1570–1577.
155. Pierie JP, Muzikansky A, Gaz RD, Faquin WC, Ott MJ 2002 The effect of surgery and radiotherapy on outcome of anaplastic thyroid carcinoma. *Ann Surg Oncol* **9**:57–64.
156. Swaak-Kragten AT, de Wilt JH, Schmitz PI, Bontenbal M, Levendag PC 2009 Multimodality treatment for anaplastic thyroid carcinoma—treatment outcome in 75 patients. *Radiation Oncol* **92**:100–104.
157. Haigh PI, Ituarte PH, Wu HS, Treseler PA, Posner MD, Quivey JM, Duh QY, Clark OH 2001 Completely resected anaplastic thyroid carcinoma combined with adjuvant chemotherapy and irradiation is associated with prolonged survival. *Cancer* **91**:2335–2342.
158. Goutsouliak V, Hay JH 2005 Anaplastic thyroid cancer in British Columbia 1985–1999: a population-based study. *Clin Oncol (R Coll Radiol)* **17**:75–78.
159. Brignardello E, Gallo M, Baldi I, Palestini N, Piovesan A, Grossi E, Ciccone G, Boccuzzi G 2007 Anaplastic thyroid carcinoma: clinical outcome of 30 consecutive patients referred to a single institution in the past 5 years. *Eur J Endocrinol* **156**:425–430.
160. Kihara M, Miyachi A, Yamauchi A, Yokomise H 2004 Prognostic factors of anaplastic thyroid carcinoma. *Surg Today* **34**:394–398.
161. De Crevoisier R, Baudin E, Bachelot A, Lebourleux S, Travagli JP, Caillou B, Schlumberger M 2004 Combined treatment of anaplastic thyroid carcinoma with surgery, chemotherapy, and hyperfractionated accelerated external radiotherapy. *Int J Radiat Oncol Biol Phys* **60**:1137–1143.
162. Schlumberger M, Parmentier C, Delisle MJ, Couette JE, Droz JP, Sarrazin D 1991 Combination therapy for anaplastic giant cell thyroid carcinoma. *Cancer* **67**:564–566.
163. Chen J, Tward JD, Shrieve DC, Hitchcock YJ 2008 Surgery and radiotherapy improves survival in patients with anaplastic thyroid carcinoma: analysis of the surveillance, epidemiology, and end results 1983–2002. *Am J Clin Oncol* **31**:460–464.
164. Ito KI, Hanamura T, Murayama K, Okada T, Watanabe T, Harada M, Ito T, Koyama H, Kanai T, Maeno K, Mochizuki Y, Amano J 2012 Multimodality therapeutic outcomes in anaplastic thyroid carcinoma: improved survival in subgroups of patients with localized primary tumors. *Head Neck* **34**:230–237.
165. Kim JH, Leeper RD 1983 Treatment of anaplastic giant and spindle cell carcinoma of the thyroid gland with combination adriamycin and radiation therapy. A new approach. *Cancer* **52**:954–957.
166. Tennvall J, Lundell G, Wahlberg P, Bergenfelz A, Grimelius L, Akerman M, Hjelm Skog AL, Wallin G 2002 Anaplastic thyroid carcinoma: three protocols combining doxorubicin, hyperfractionated radiotherapy and surgery. *Br J Cancer* **86**:1848–1853.
167. Levendag PC, De Porre PM, van Putten WL 1993 Anaplastic carcinoma of the thyroid gland treated by radiation therapy. *Int J Radiat Oncol Biol Phys* **26**:125–128.
168. Wang Y, Tsang R, Asa S, Dickson B, Arenovich T, Brierley J 2006 Clinical outcome of anaplastic thyroid carcinoma treated with radiotherapy of once- and twice-daily fractionation regimens. *Cancer* **107**:1786–1792.
169. Besic N, Hocevar M, Zgajnar J, Pogacnik A, Grazio-Frkovic S, Auersperg M 2005 Prognostic factors in anaplastic carcinoma of the thyroid—a multivariate survival analysis of 188 patients. *Langenbecks Arch Surg* **390**:203–208.
170. Voutilainen PE, Multanen M, Haapiainen RK, Leppaniemi AK, Sivula AH 1999 Anaplastic thyroid carcinoma survival. *World J Surg* **23**:975–978; discussion 978–979.
171. Pasieka JL 2003 Anaplastic thyroid cancer. *Curr Opin Oncol* **15**:78–83.
172. Shaha AR 2008 Airway management in anaplastic thyroid carcinoma. *Laryngoscope* **118**:1195–1198.
173. Holting T, Meybier H, Buhr H 1989 [Problems of tracheotomy in locally invasive anaplastic thyroid cancer]. *Langenbecks Arch Chir* **374**:72–76.
174. Veness MJ, Porter GS, Morgan GJ 2004 Anaplastic thyroid carcinoma: dismal outcome despite current treatment approach. *ANZ J Surg* **74**:559–562.
175. Kobayashi T, Asakawa H, Umeshita K, Takeda T, Maruyama H, Matsuzuka F, Monden M 1996 Treatment of 37 patients with anaplastic carcinoma of the thyroid. *Head Neck* **18**:36–41.
176. Busnardo B, Daniele O, Pelizzo MR, Mazzarotto R, Nacamulli D, Devido D, Mian C, Girelli ME 2000 A multimodality therapeutic approach in anaplastic thyroid carcinoma: study on 39 patients. *J Endocrinol Invest* **23**:755–761.
177. Bhatia A, Rao A, Ang KK, Garden AS, Morrison WH, Rosenthal DI, Evans DB, Clayman G, Sherman SI, Schwartz DL 2010 Anaplastic thyroid cancer: clinical outcomes with conformal radiotherapy. *Head Neck* **32**:829–836.

178. Derbel O, Limem S, Segura-Ferlay C, Lifante JC, Carrie C, Peix JL, Borson-Chazot F, Bournaud C, Droz JP, de la Fouchardiere C 2011 Results of combined treatment of anaplastic thyroid carcinoma (ATC). *BMC Cancer* **11**:469.
179. Sherman EJ, Lim SH, Ho AL, Ghossein RA, Fury MG, Shaha AR, Rivera M, Lin O, Wolden S, Lee NY, Pfister DG 2011 Concurrent doxorubicin and radiotherapy for anaplastic thyroid cancer: a critical re-evaluation including uniform pathologic review. *Radiother Oncol* **101**:425–430.
180. Lee N, Xia P, Quivey JM, Sultanem K, Poon I, Akazawa C, Akazawa P, Weinberg V, Fu KK 2002 Intensity-modulated radiotherapy in the treatment of nasopharyngeal carcinoma: an update of the UCSF experience. *Int J Radiat Oncol Biol Phys* **53**:12–22.
181. Bhide SA, Kazi R, Newbold K, Harrington KJ, Nutting CM 2010 The role of intensity-modulated radiotherapy in head and neck cancer. *Indian J Cancer* **47**:267–273.
182. Nutting CM, Convery DJ, Cosgrove VP, Rowbottom C, Vini L, Harmer C, Dearnaley DP, Webb S 2001 Improvements in target coverage and reduced spinal cord irradiation using intensity-modulated radiotherapy (IMRT) in patients with carcinoma of the thyroid gland. *Radiother Oncol* **60**:173–180.
183. Schwartz DL, Lobo MJ, Ang KK, Morrison WH, Rosenthal DI, Ahamad A, Evans DB, Clayman G, Sherman SI, Garden AS 2009 Postoperative external beam radiotherapy for differentiated thyroid cancer: outcomes and morbidity with conformal treatment. *Int J Radiat Oncol Biol Phys* **74**:1083–1091.
184. Brierley J, Rumble RB, Warde P, and members of the IMRT Indications Expert Panel. The Role of IMRT in Thyroid Cancers: Cancer Care Ontario. Available at <https://www.cancercare.on.ca/common/pages/UserFile.aspx?fileId=87005> (accessed August 23, 2012).
185. Ain KB, Egorin MJ, DeSimone PA 2000 Treatment of anaplastic thyroid carcinoma with paclitaxel: phase 2 trial using ninety-six-hour infusion. Collaborative anaplastic thyroid cancer health intervention trials (CATCHIT) group. *Thyroid* **10**:587–594.
186. Troch M, Koperek O, Scheuba C, Dieckmann K, Hoffmann M, Niederle B, Raderer M 2010 High efficacy of concomitant treatment of undifferentiated (anaplastic) thyroid cancer with radiation and docetaxel. *J Clin Endocrinol Metab* **95**:E54–57.
187. Foote RL, Molina JR, Kasperbauer JL, Lloyd RV, McIver B, Morris JC, Grant CS, Thompson GB, Richards ML, Hay ID, Smallridge RC, Bible KC 2011 Enhanced survival in locoregionally confined anaplastic thyroid carcinoma: a single-institution experience using aggressive multimodal therapy. *Thyroid* **21**:25–30.
188. Kawada K, Kitagawa K, Kamei S, Inada M, Mitsuma A, Sawaki M, Kikumori T, Fujimoto Y, Arima H, Imai T, Ando Y 2010 The feasibility study of docetaxel in patients with anaplastic thyroid cancer. *Jpn J Clin Oncol* **40**:596–599.
189. Dandekar P, Harmer C, Barbachano Y, Rhys-Evans P, Harrington K, Nutting C, Newbold K 2009 Hyperfractionated accelerated radiotherapy (HART) for anaplastic thyroid carcinoma: toxicity and survival analysis. *Int J Radiat Oncol Biol Phys* **74**:518–521.
190. Tennvall J, Lundell G, Hallquist A, Wahlberg P, Wallin G, Tibblin S 1994 Combined doxorubicin, hyperfractionated radiotherapy, and surgery in anaplastic thyroid carcinoma. Report on two protocols. The Swedish Anaplastic Thyroid Cancer Group. *Cancer* **74**:1348–1354.
191. Shimaoka K, Schoenfeld DA, DeWys WD, Creech RH, DeConti R 1985 A randomized trial of doxorubicin versus doxorubicin plus cisplatin in patients with advanced thyroid carcinoma. *Cancer* **56**:2155–2160.
192. Mooney CJ, Nagaiah G, Fu P, Wasman JK, Cooney MM, Savvides PS, Bokar JA, Dowlati A, Wang D, Agarwala SS, Flick SM, Hartman PH, Ortiz JD, Lavertu PN, Remick SC 2009 A phase II trial of fosbretabulin in advanced anaplastic thyroid carcinoma and correlation of baseline serum-soluble intracellular adhesion molecule-1 with outcome. *Thyroid* **19**:233–240.
193. Dowlati A, Robertson K, Cooney M, Petros WP, Stratford M, Jesberger J, Rafie N, Overmoyer B, Makkar V, Stambler B, Taylor A, Waas J, Lewin JS, McCrae KR, Remick SC 2002 A phase I pharmacokinetic and translational study of the novel vascular targeting agent combretastatin a-4 phosphate on a single-dose intravenous schedule in patients with advanced cancer. *Cancer Res* **62**:3408–3416.
194. Gupta-Abramson V, Troxel AB, Nellore A, Puttaswamy K, Redlinger M, Ransone K, Mandel SJ, Flaherty KT, Loevner LA, O'Dwyer PJ, Brose MS 2008 Phase II trial of sorafenib in advanced thyroid cancer. *J Clin Oncol* **26**:4714–4719.
195. Kloos RT, Ringel MD, Knopp MV, Hall NC, King M, Stevens R, Liang J, Wakely PE Jr, Vasko VV, Saji M, Rittenberry J, Wei L, Arbogast D, Collamore M, Wright JJ, Grever M, Shah MH 2009 Phase II trial of sorafenib in metastatic thyroid cancer. *J Clin Oncol* **27**:1675–1684.
196. Cohen EE, Rosen LS, Vokes EE, Kies MS, Forastiere AA, Worden FP, Kane MA, Sherman E, Kim S, Bycott P, Tورتorici M, Shalinsky DR, Liao KF, Cohen RB 2008 Axitinib is an active treatment for all histologic subtypes of advanced thyroid cancer: results from a phase II study. *J Clin Oncol* **26**:4708–4713.
197. Pennell NA, Daniels GH, Haddad RI, Ross DS, Evans T, Wirth LJ, Fidias PH, Temel JS, Gurubhagavatula S, Heist RS, Clark JR, Lynch TJ 2008 A phase II study of gefitinib in patients with advanced thyroid cancer. *Thyroid* **18**:317–323.
198. Ha HT, Lee JS, Urba S, Koenig RJ, Sisson J, Giordano T, Worden FP 2010 A phase II study of imatinib in patients with advanced anaplastic thyroid cancer. *Thyroid* **20**:975–980.
199. Salvati M, Frati A, Rocchi G, Masciangelo R, Antonaci A, Gagliardi FM, Delfini R 2001 Single brain metastasis from thyroid cancer: report of twelve cases and review of the literature. *J Neurooncol* **51**:33–40.
200. Chiu AC, Delpassand ES, Sherman SI 1997 Prognosis and treatment of brain metastases in thyroid carcinoma. *J Clin Endocrinol Metab* **82**:3637–3642.
201. Murata Y, Ogawa Y, Yoshida S, Kubota K, Itoh S, Fukumoto M, Nishioka A, Moriki T, Maeda H, Tanaka Y 2004 Utility of initial MRI for predicting extent of residual disease after neoadjuvant chemotherapy: analysis of 70 breast cancer patients. *Oncol Rep* **12**:1257–1262.
202. Koutras AK, Krikelis D, Alexandrou N, Starakis I, Kalofonos HP 2007 Brain metastasis in renal cell cancer responding to sunitinib. *Anticancer Res* **27**:4255–4257.
203. Agarwal S, Sane R, Ohlfest JR, Elmquist WF 2011 The role of the breast cancer resistance protein (ABCG2) in the distribution of sorafenib to the brain. *J Pharmacol Exp Ther* **336**:223–233.
204. Ryken TC, McDermott M, Robinson PD, Ammirati M, Andrews DW, Asher AL, Burri SH, Cobbs CS, Gaspar LE,

- Kondziolka D, Linskey ME, Loeffler JS, Mehta MP, Mikkelsen T, Olson JJ, Paleologos NA, Patchell RA, Kalkanis SN 2010 The role of steroids in the management of brain metastases: a systematic review and evidence-based clinical practice guideline. *J Neurooncol* **96**:103–114.
205. Mikkelsen T, Paleologos NA, Robinson PD, Ammirati M, Andrews DW, Asher AL, Burri SH, Cobbs CS, Gaspar LE, Kondziolka D, Linskey ME, Loeffler JS, McDermott M, Mehta MP, Olson JJ, Patchell RA, Ryken TC, Kalkanis SN 2010 The role of prophylactic anticonvulsants in the management of brain metastases: a systematic review and evidence-based clinical practice guideline. *J Neurooncol* **96**: 97–102.
206. Forsyth PA, Weaver S, Fulton D, Brasher PM, Sutherland G, Stewart D, Hagen NA, Barnes P, Cairncross JG, DeAngelis LM 2003 Prophylactic anticonvulsants in patients with brain tumour. *Can J Neurol Sci* **30**:106–112.
207. Tickoo SK, Pittas AG, Adler M, Fazzari M, Larson SM, Robbins RJ, Rosai J 2000 Bone metastases from thyroid carcinoma: a histopathologic study with clinical correlates. *Arch Pathol Lab Med* **124**:1440–1447.
208. Pittas AG, Adler M, Fazzari M, Tickoo S, Rosai J, Larson SM, Robbins RJ 2000 Bone metastases from thyroid carcinoma: clinical characteristics and prognostic variables in one hundred forty-six patients. *Thyroid* **10**:261–268.
209. Aapro M, Abrahamsson PA, Body JJ, Coleman RE, Colomer R, Costa L, Crino L, Dirix L, Gnant M, Gralow J, Hadji P, Hortobagyi GN, Jonat W, Lipton A, Monnier A, Paterson AH, Rizzoli R, Saad F, Thurlimann B 2008 Guidance on the use of bisphosphonates in solid tumours: recommendations of an international expert panel. *Ann Oncol* **19**:420–432.
210. Hortobagyi GN, Theriault RL, Porter L, Blayney D, Lipton A, Sinoff C, Wheeler H, Simeone JF, Seaman J, Knight RD 1996 Efficacy of pamidronate in reducing skeletal complications in patients with breast cancer and lytic bone metastases. Protocol 19 Aredia Breast Cancer Study Group. *N Engl J Med* **335**:1785–1791.
211. Rosen LS, Gordon D, Kaminski M, Howell A, Belch A, Mackey J, Apffelstaedt J, Hussein MA, Coleman RE, Reitsma DJ, Chen BL, Seaman JJ 2003 Long-term efficacy and safety of zoledronic acid compared with pamidronate disodium in the treatment of skeletal complications in patients with advanced multiple myeloma or breast carcinoma: a randomized, double-blind, multicenter, comparative trial. *Cancer* **98**:1735–1744.
212. Roodman GD 2004 Mechanisms of bone metastasis. *N Engl J Med* **350**:1655–1664.
213. Favus MJ 2010 Bisphosphonates for osteoporosis. *N Engl J Med* **363**:2027–2035.
214. Stopeck AT, Lipton A, Body JJ, Steger GG, Tonkin K, de Boer RH, Lichinitser M, Fujiwara Y, Yardley DA, Viniegra M, Fan M, Jiang Q, Dansey R, Jun S, Braun A 2010 Denosumab compared with zoledronic acid for the treatment of bone metastases in patients with advanced breast cancer: a randomized, double-blind study. *J Clin Oncol* **28**:5132–5139.
215. Antoch G, Vogt FM, Freudenberg LS, Nazaradeh F, Goehde SC, Barkhausen J, Dahmen G, Bockisch A, Debatin JF, Ruehm SG 2003 Whole-body dual-modality PET/CT and whole-body MRI for tumor staging in oncology. *JAMA* **290**:3199–3206.
216. Muresan MM, Olivier P, Leclere J, Sirveaux F, Brunaud L, Klein M, Zarnegar R, Weryha G 2008 Bone metastases from differentiated thyroid carcinoma. *Endocr Relat Cancer* **15**:37–49.
217. Schirrmeyer H, Guhlmann A, Elsner K, Kotzerke J, Glatting G, Rentschler M, Neumaier B, Trager H, Nussle K, Reske SN 1999 Sensitivity in detecting osseous lesions depends on anatomic localization: planar bone scintigraphy versus 18F PET. *J Nucl Med* **40**:1623–1629.
218. Harrington KD 1997 Orthopedic surgical management of skeletal complications of malignancy. *Cancer* **80**: 1614–1627.
219. Patchell RA, Tibbs PA, Regine WF, Payne R, Saris S, Kryscio RJ, Mohiuddin M, Young B 2005 Direct decompressive surgical resection in the treatment of spinal cord compression caused by metastatic cancer: a randomised trial. *Lancet* **366**:643–648.
220. Dahl PR, Brodland DG, Goellner JR, Hay ID 1997 Thyroid carcinoma metastatic to the skin: a cutaneous manifestation of a widely disseminated malignancy. *J Am Acad Dermatol* **36**:531–537.
221. Capezzone M, Giannasio P, De Sanctis D, Bellitti P, Vena P, Morabito E, Bruno R 2006 Skin metastases from anaplastic thyroid carcinoma. *Thyroid* **16**:513–514.
222. Dedecjus M, Tazbir J, Kaurzel Z, Lewinski A, Strozyk G, Brzezinski J 2007 Selective embolization of thyroid arteries as a prereseptive and palliative treatment of thyroid cancer. *Endocr Relat Cancer* **14**:847–852.
223. Tazbir J, Dedecjus M, Kaurzel Z, Lewinski A, Brzezinski J 2005 Selective embolization of thyroid arteries (SETA) as a palliative treatment of inoperable anaplastic thyroid carcinoma (ATC). *Neuro Endocrinol Lett* **26**:401–406.
224. Seo YL, Yoon DY, Lim KJ, Cha JH, Yun EJ, Choi CS, Bae SH 2010 Locally advanced thyroid cancer: can CT help in prediction of extrathyroidal invasion to adjacent structures? *AJR Am J Roentgenol* **195**:W240–244.
225. Panzironi G, Rainaldi R, Ricci F, Casale A, De Vargas Macciucca M 2003 Gray-scale and color Doppler findings in bilateral internal jugular vein thrombosis caused by anaplastic carcinoma of the thyroid. *J Clin Ultrasound* **31**:111–115.
226. Sugimoto S, Doihara H, Ogasawara Y, Aoe M, Sano S, Shimizu N 2006 Intraatrial extension of thyroid cancer: a case report. *Acta Med Okayama* **60**:135–140.
227. Lyman GH, Khorana AA, Falanga A, Clarke-Pearson D, Flowers C, Jahanzeb M, Kakkar A, Kuderer NM, Levine MN, Liebman H, Mendelson D, Raskob G, Somerfield MR, Thodiyil P, Trent D, Francis CW 2007 American Society of Clinical Oncology guideline: recommendations for venous thromboembolism prophylaxis and treatment in patients with cancer. *J Clin Oncol* **25**:5490–5505.
228. Astrow AB, Popp B 2011 The Palliative Care Information Act in real life. *N Engl J Med* **364**:1885–1887.
229. Center to Advance Palliative Care. Analysis of US Hospital Palliative Care Programs: 2010 Snapshot. Available at www.capc.org/news-and-events/releases/analysis-of-us-hospital-palliative-care-programs-2010-snapshot.pdf/file_view (accessed August 23, 2012).
230. Center to Advance Palliative Care. Growth of Palliative Care in US Hospitals 2012 Snapshot. Available at www.capc.org/capc-growth-analysis-snapshot-2011.pdf (accessed August 23, 2012).
231. Rodriguez JM, Pinero A, Ortiz S, Moreno A, Sola J, Soria T, Robles R, Parrilla P 2000 Clinical and histological differences in anaplastic thyroid carcinoma. *Eur J Surg* **166**: 34–38.

232. Kim JH, Leeper RD 1987 Treatment of locally advanced thyroid carcinoma with combination doxorubicin and radiation therapy. *Cancer* **60**:2372–2375.
233. Hadar T, Mor C, Shvero J, Levy R, Segal K 1993 Anaplastic carcinoma of the thyroid. *Eur J Surg Oncol* **19**:511–516.
234. Kitamura Y, Shimizu K, Nagahama M, Sugino K, Ozaki O, Mimura T, Ito K, Tanaka S 1999 Immediate causes of death in thyroid carcinoma: clinicopathological analysis of 161 fatal cases. *J Clin Endocrinol Metab* **84**:4043–4049.
235. Wong CS, Van Dyk J, Simpson WJ 1991 Myelopathy following hyperfractionated accelerated radiotherapy

for anaplastic thyroid carcinoma. *Radiother Oncol* **20**: 3–9.

Address correspondence to:
Robert C. Smallridge, M.D.
Mayo Clinic
4500 San Pablo Road
Jacksonville, FL, 32224

E-mail: smallridge.robert@mayo.edu